SERVIZIO SANITARIO REGIONALE
EMILIA-ROMAGNA
Azienda Unità Sanitaria Locale di Ferrara

Metodiche radiologiche di diagnosi delle neoformazioni pancreatiche

Dr. Massimo Tilli
U.O. interaziendale di radiologia diagnostica e interventistica
AUSL Ferrara
m.tilli@ausl.fe.it

Cosa è richiesto all'imaging?

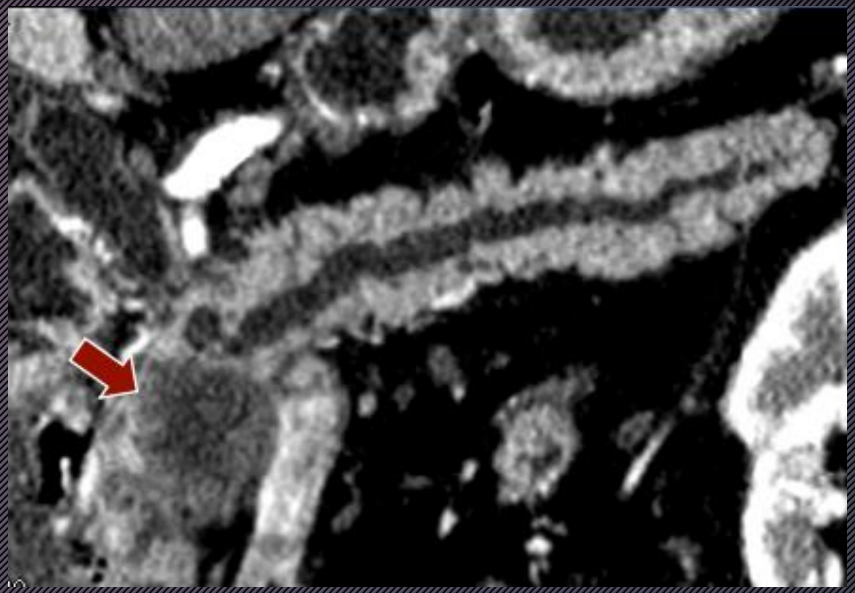

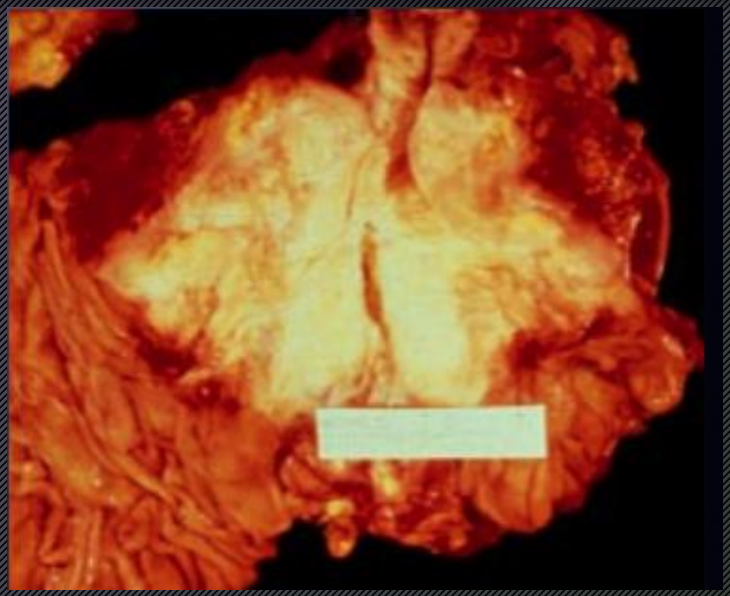

- *Identificazione*
- *Caratterizzazione*
- *Stadiazione e resecabilità*
- *Follow-up*

Quale metodica?

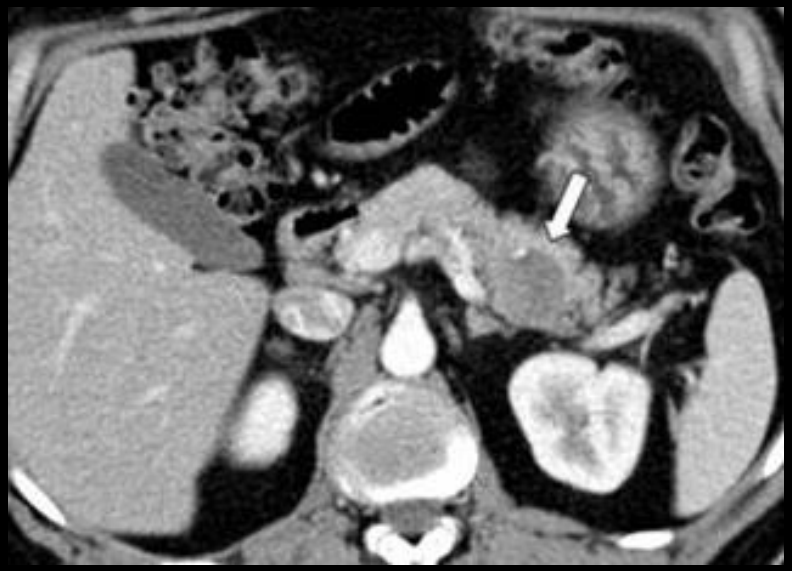

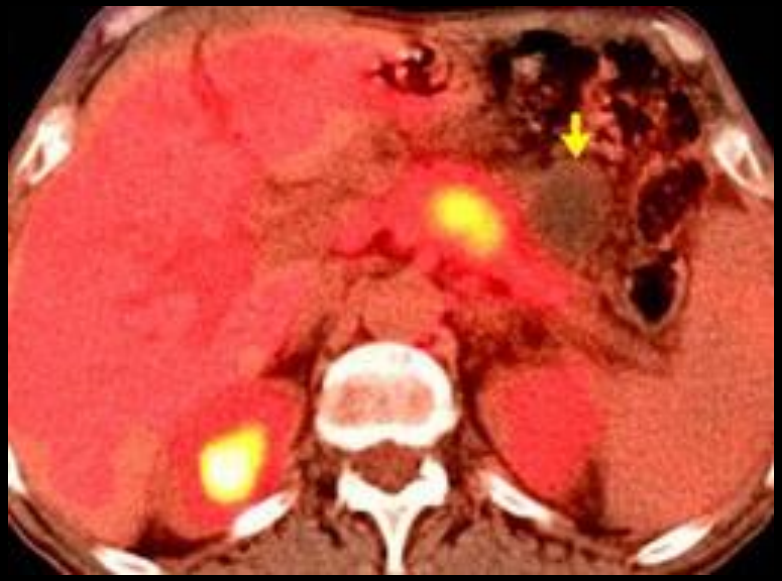

Identificazione della lesione

US: imaging di I livello

Accuratezza 50-70%

1. Esplorabilita'
   (obesita', meteorismo...)
2. Dimensioni del nodulo < 2 cm
3. Localizzazione del nodulo
   (coda del pancreas)
4. Marcata "operatore dipendenza"

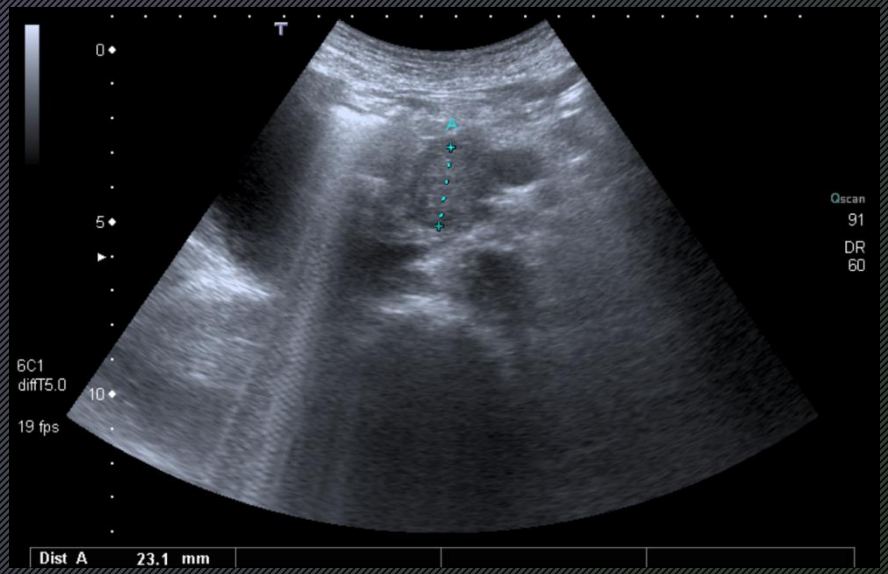

Identificazione della lesione

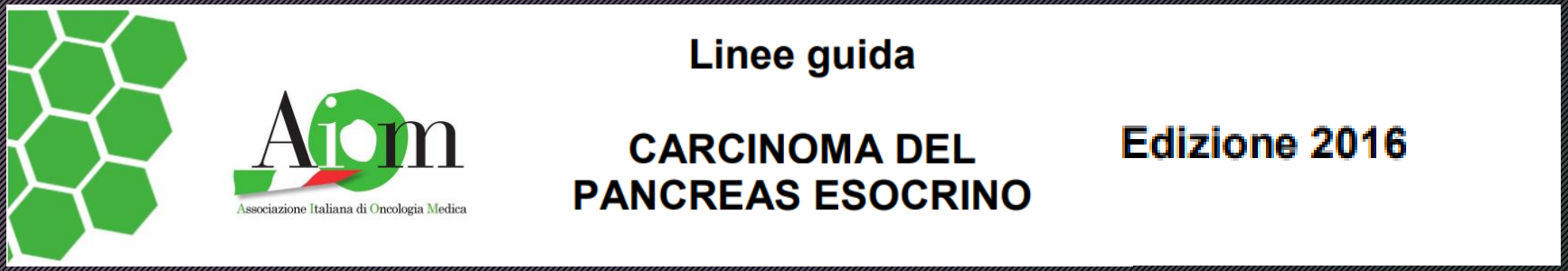

- TC con mdc: Esame di scelta per diagnosi e stadiazione (livello di evidenza IV)
- Accuratezza nel definire resecabilità: 70-85%
- Raccomandato estendere a TC torace

CLINICAL PRESENTATION | **WORKUP**

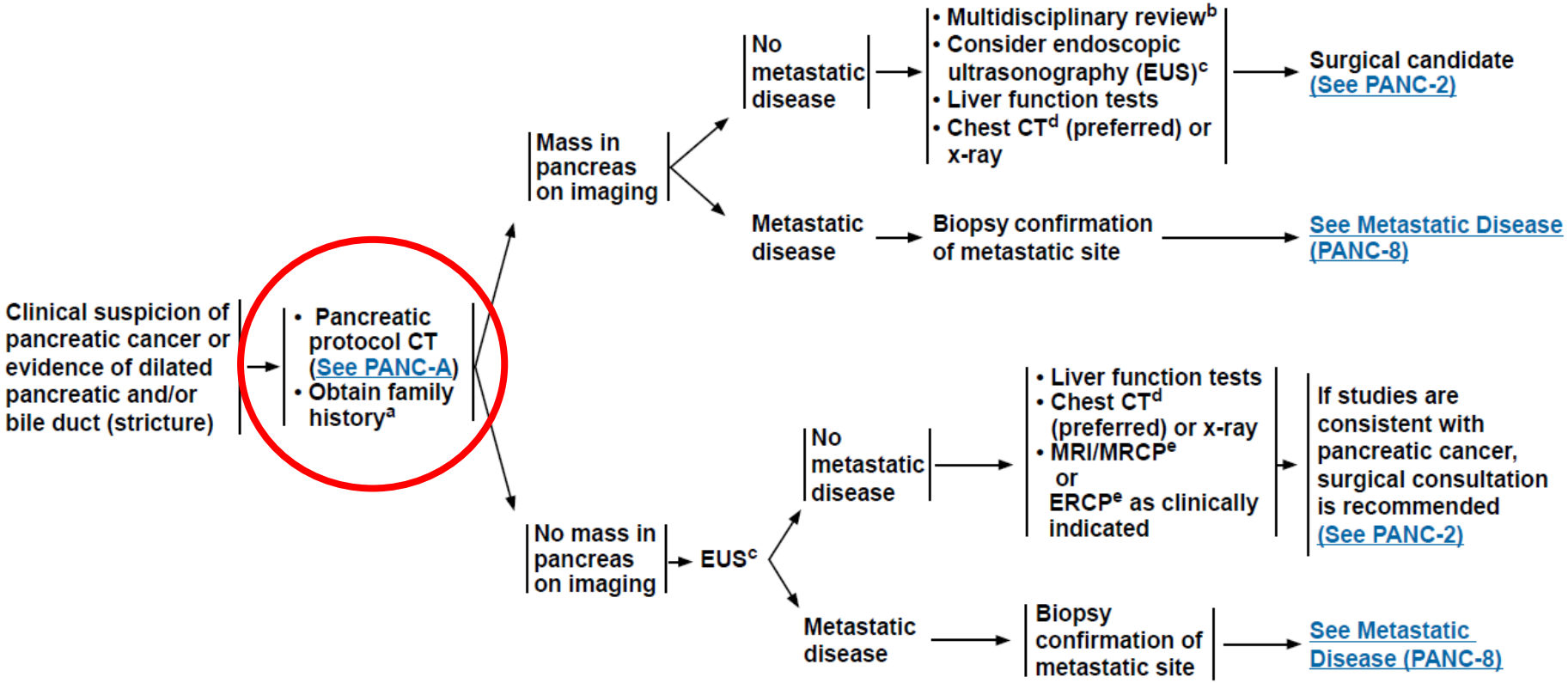

[a]If pancreatic cancer is diagnosed, consider referral for genetic counseling for patients who are young, those with a family history of cancer, or those of Ashkenazi Jewish ancestry.
[b]Multidisciplinary review should ideally involve expertise from diagnostic imaging, interventional endoscopy, medical oncology, radiation oncology, surgery, and pathology. Consider consultation with a registered dietitian.
[c]EUS to confirm primary site of involvement; EUS-FNA if clinically indicated.
[d]Imaging with contrast unless contraindicated.
[e]MRCP = magnetic resonance cholangiopancreatography; ERCP = endoscopic retrograde cholangiopancreatography

Note: All recommendations are category 2A unless otherwise indicated.
Clinical Trials: NCCN believes that the best management of any patient with cancer is in a clinical trial. Participation in clinical trials is especially encouraged.

Ottimizzazione protocolli TC !!

Ottimizzazione protocolli TC !!

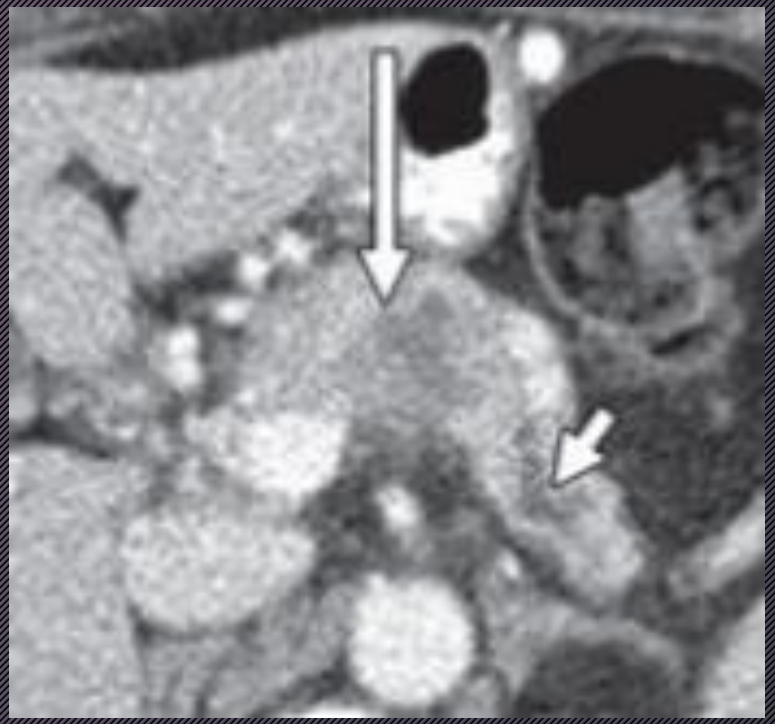

Nei pz itterici sarebbe auspicabile esguire TC prima del posizionamento di uno stent biliare !!!!!!!!

Risulta compromessa la visualizzazione dell'ostruzione biliare (TC,RM,EUS)

E' possibile l'insorgenza di pancreatite post-ERCP che limita la visualizzazione dell'interfaccia fra tumore e vasi

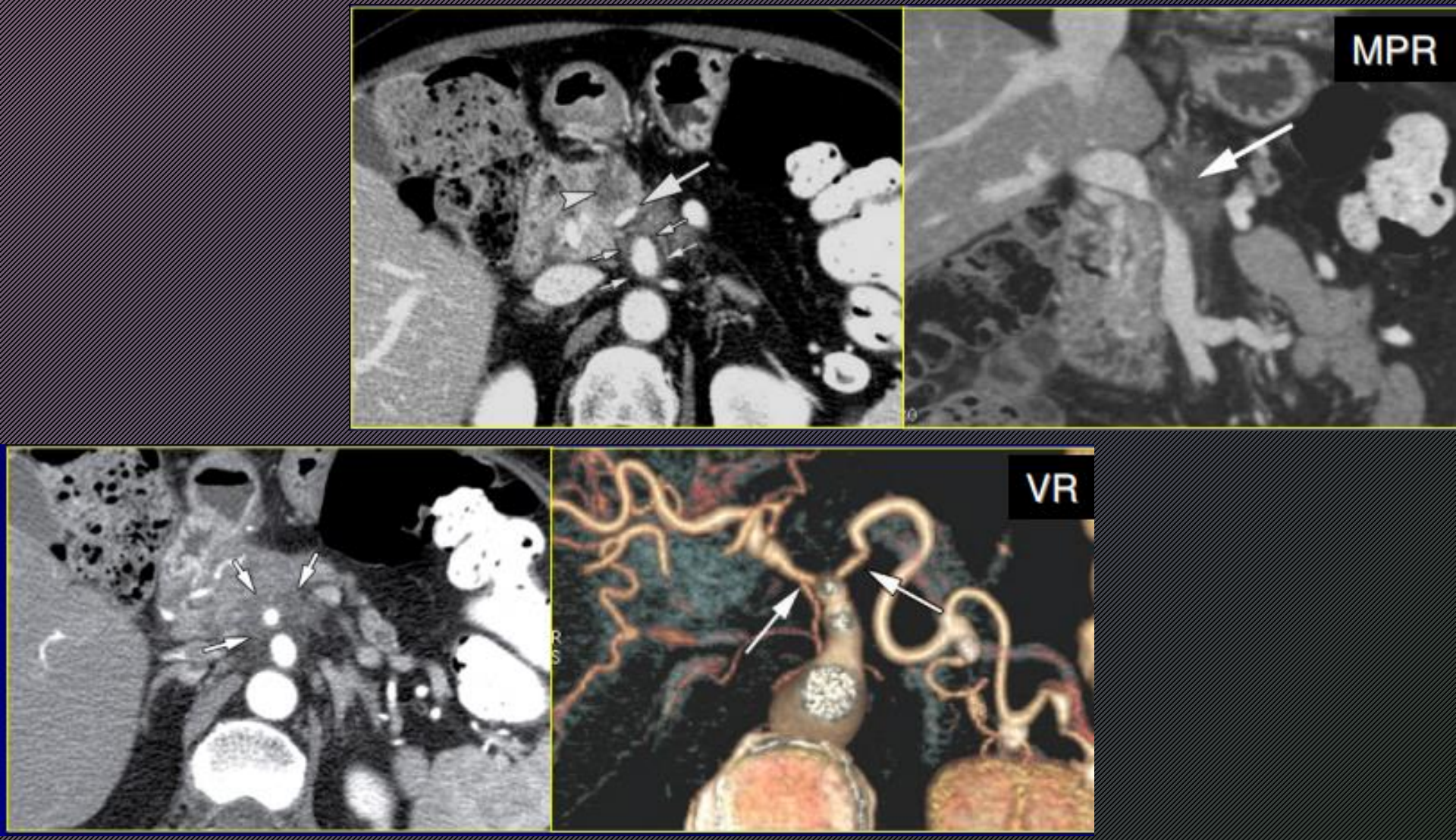

Utilità delle ricostruzione MPR e 3D nel mapping vascolare

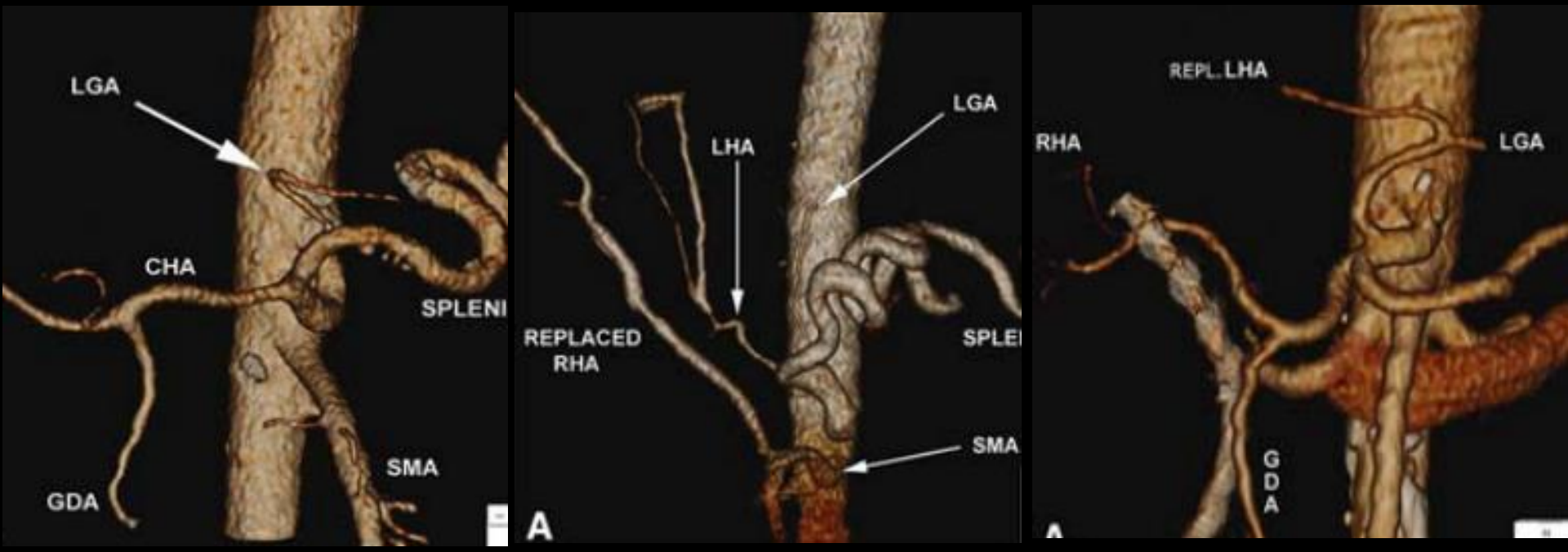

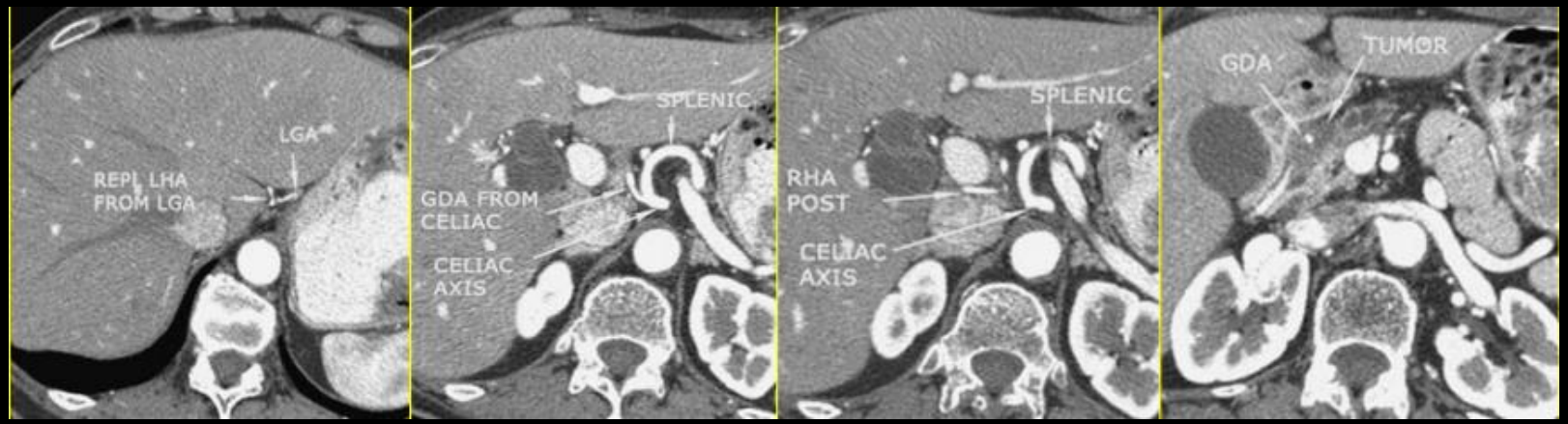

Utilità delle ricostruzione MPR e 3D nel mapping vascolare

Semeiotica radiologica

Segni diretti

- *Lesione ipovascolare*
- *Invasione vascolare*

Segni indiretti

- *Dilatazione del Wirsung*
- *Dilatazione VBP e VBI*
- *Metastasi*

Casi “facili”

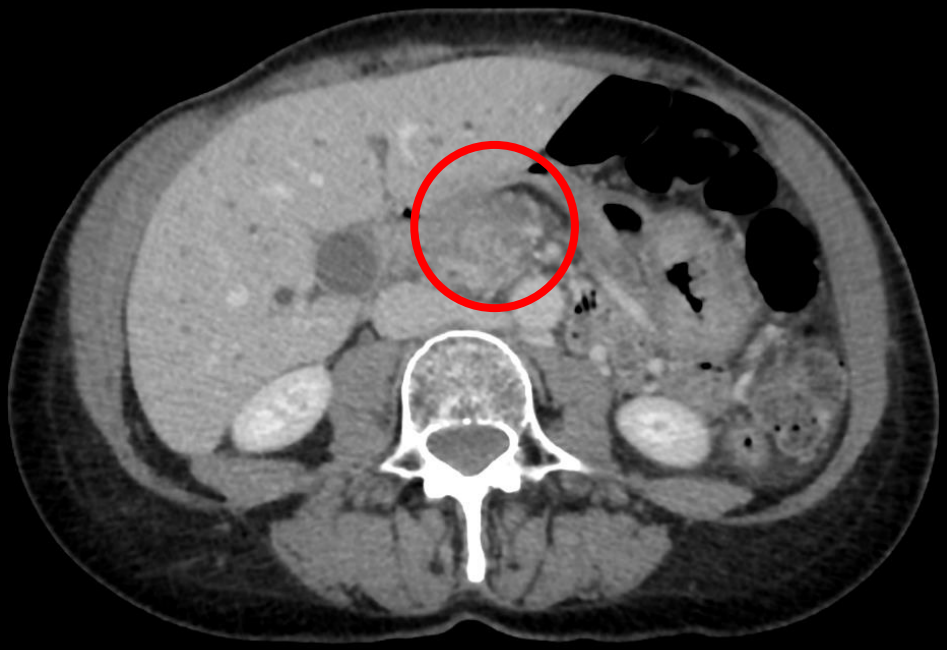

Casi “difficili”

Criticità : Tumori piccoli

Small (≤20 mm) Pancreatic Adenocarcinomas: Analysis of Enhancement Patterns and Secondary Signs with Multiphasic Multidetector CT[1]

Radiology

Limitata sensibilità (77%) nei piccoli tumori (< 2cm)

Spesso sono isodensi rispetto al parenchima in TC (e a volte anche in RM) e l'individuazione è affidata ai segni secondari

Criticità : Tumori piccoli

	Cellular Differentiation*			Estimated Tumor Stage†			Tumor Location			
Tumor Size	Well	Moderate	Poor	≤T2	T3	T4	Uncinate Process	Head	Body	Tail
Undetectable tumor ($n = 9$)	20 (1/5)	60 (3/5)	20 (1/5)	78 (7/9)	0 (0/9)	22 (2/9)	0 (0/9)	56 (5/9)	11 (1/9)	33 (3/9)
Detectable tumor ($n = 24$)										
≤20 mm ($n = 21$)	0 (0/8)	88 (7/8)	12 (1/8)	48 (10/21)	43 (9/21)	10 (2/21)	19 (4/21)	62 (13/21)	14 (3/21)	5 (1/21)
21–30 mm ($n = 3$)	0 (0/3)	100 (3/3)	0 (0/3)	0 (0/3)	100 (3/3)	0 (0/3)	0 (0/3)	100 (3/3)	0 (0/3)	0 (0/3)
All tumors ($n = 33$)	6 (1/16)	81 (13/16)	12 (2/16)	52 (17/33)	36 (12/33)	12 (4/33)	12 (4/33)	64 (21/33)	12 (4/33)	12 (4/33)

Non sempre i tumori piccoli hanno un T basso….

< 1/3 dei tumori<2 cm erano T1

50% dei tumori < 2 cm erano T3

10% dei tumori < 2 cm erano T4

Criticità : Tumori isodensi

Visually Isoattenuating Pancreatic Adenocarcinoma at Dynamic-Enhanced CT: Frequency, Clinical and Pathologic Characteristics, and Diagnosis at Imaging Examinations[1]

***10-14%** di tutti gli adenok pancreatici è isodenso (la maggioranza <2cm)*

differenti caratteristiche istopatologiche

più acini residui, alta densità di microvasi, stroma fibroso lasso più rappresentato (maggiore reazione desmoplastica)

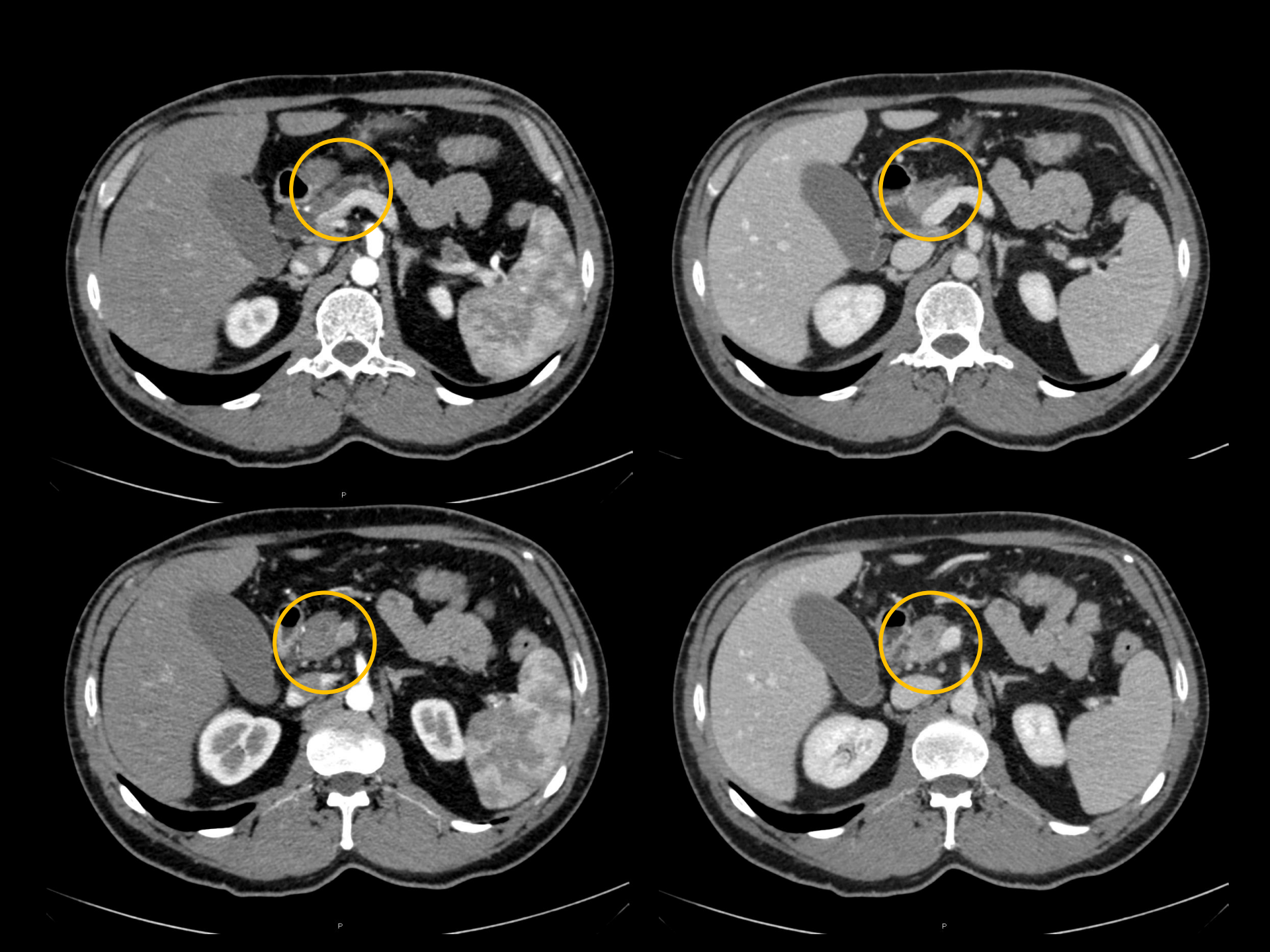
P
P
P

Criticità : Tumori isodensi

88% dei t. < 2 cm isodensi

Ricerca dei

segni secondari

Completamento

con altre metodiche

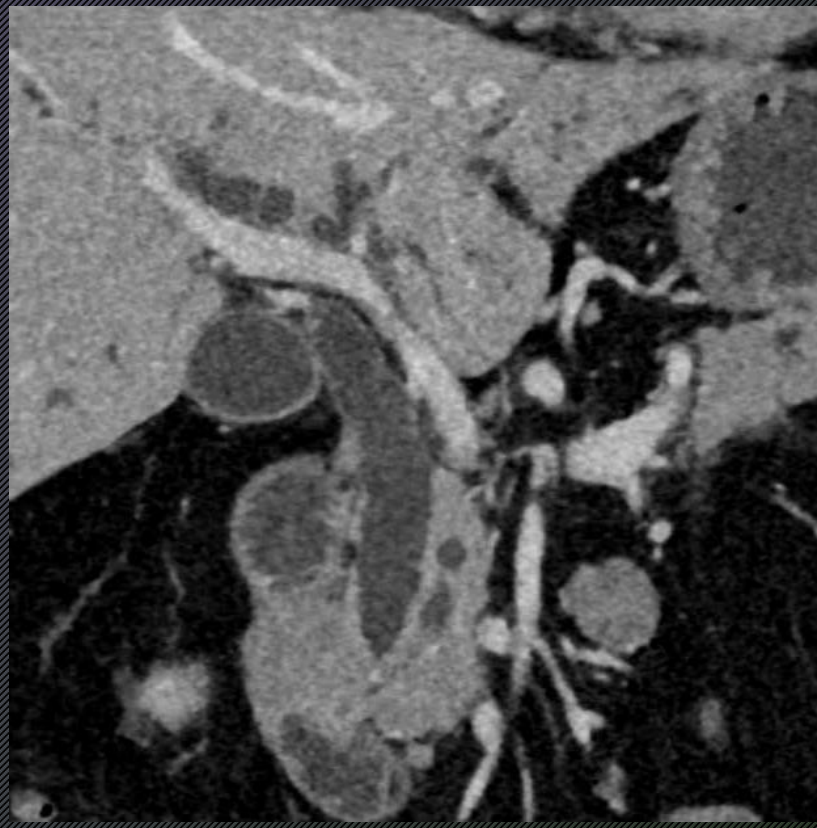

Segni secondari

Attenzione al WIRSUNG

Interruzione del dotto pancreatico

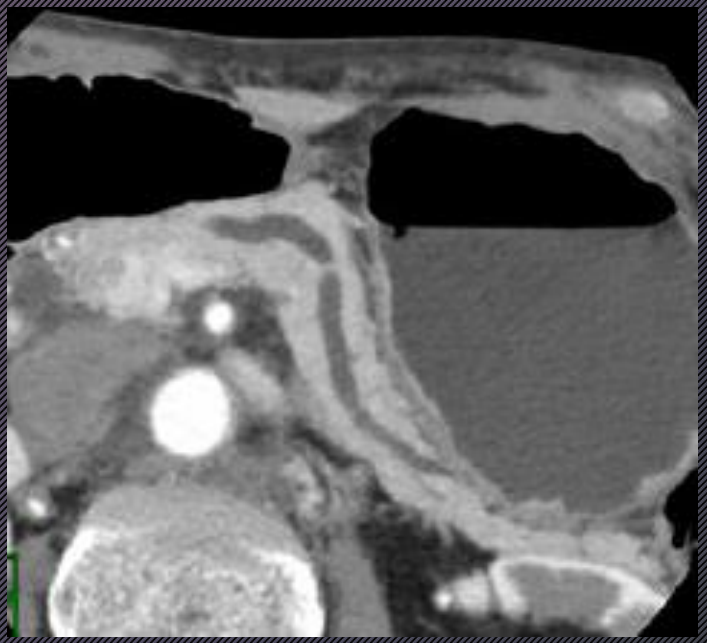

"Double duct sign"

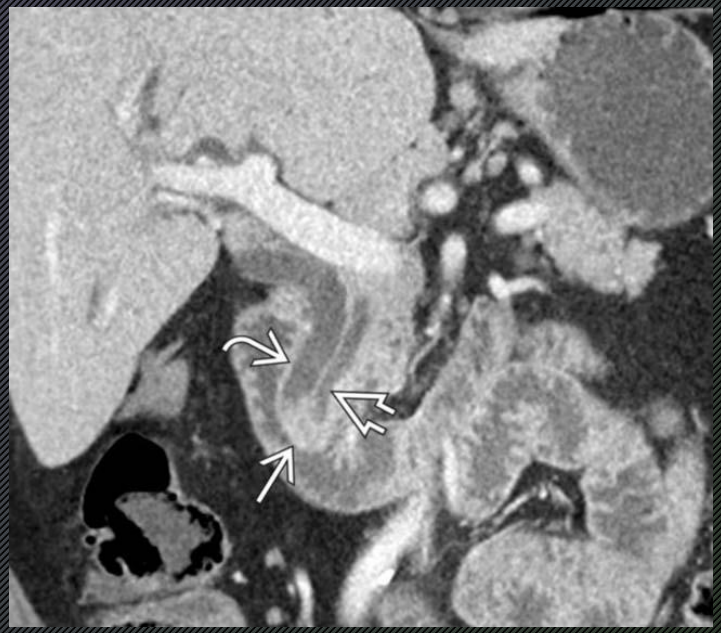

Problemi DD

“Double duct sign”

Altamente suggestivo
(ma NON diagnostico)

Patologie maligne

k ampollare
colangiocarcinoma del coledoco distale
ca. duodenale
linfoma

Patologie benigne

pancreatite cronica
stenosi ampollare

Segni secondari

Attenzione al Trofismo

Atrofia parenchimale a monte

Area focale SOLIDA in un pancreas con sostituzione adiposa

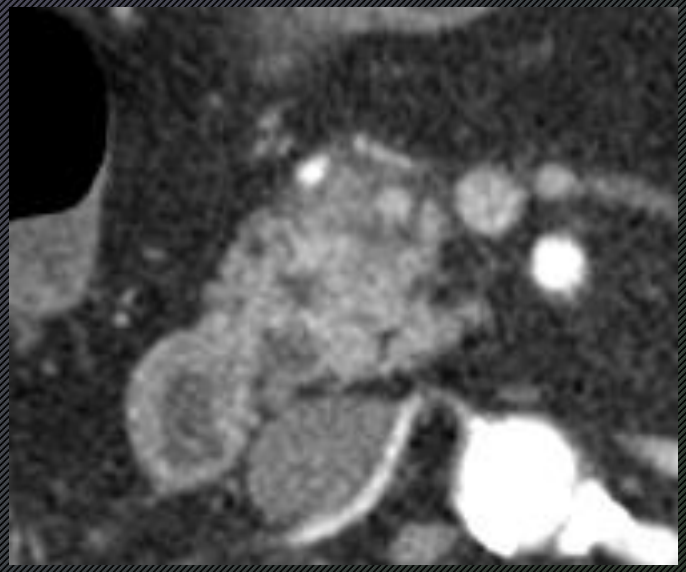

Criticità : Tumori isodensi

- Lesioni focali iso-attenuanti alla TC con MDC

- Donna, 56 aa
- Dolore retro-sternale
- Calo ponderale
- Aumento lipasi/amilasi
- Storia familiare di CA pancreas
- CA 19.9 normale
- Wirsung dilatato all’ecografia

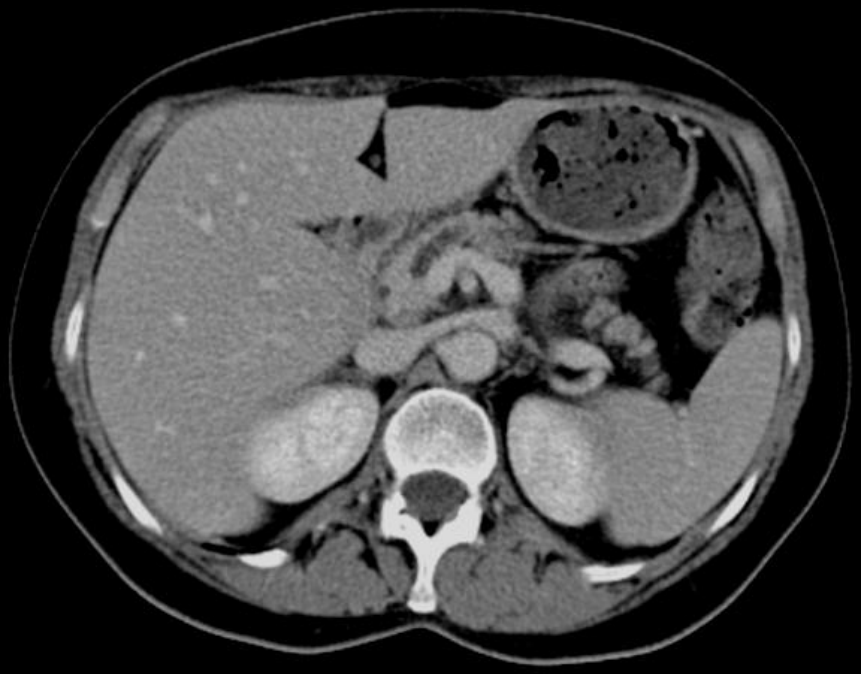

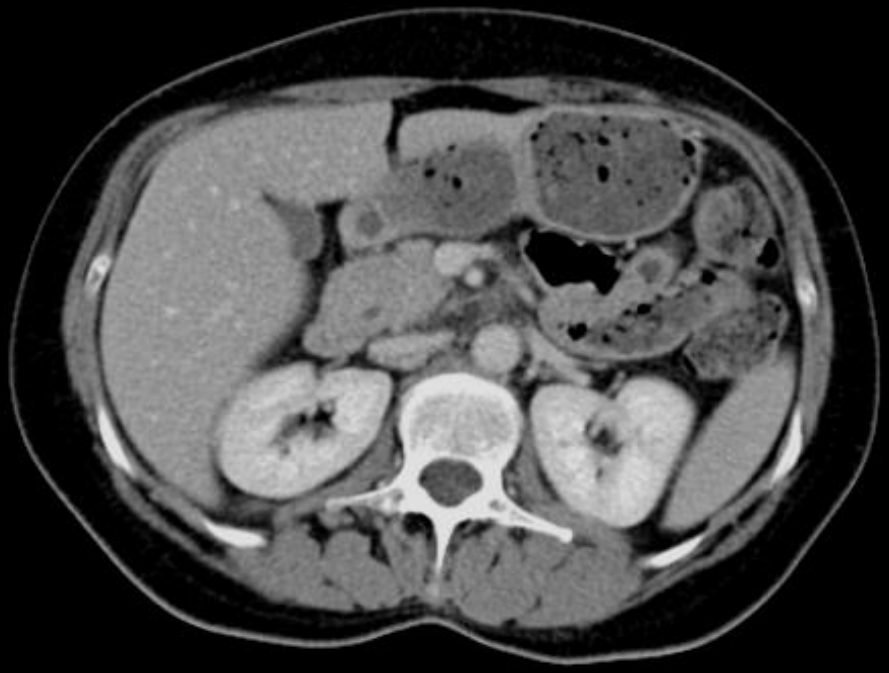

- Dilatazione del Wirsung
- Lesione iso-attenuante

- Prossimo passo?

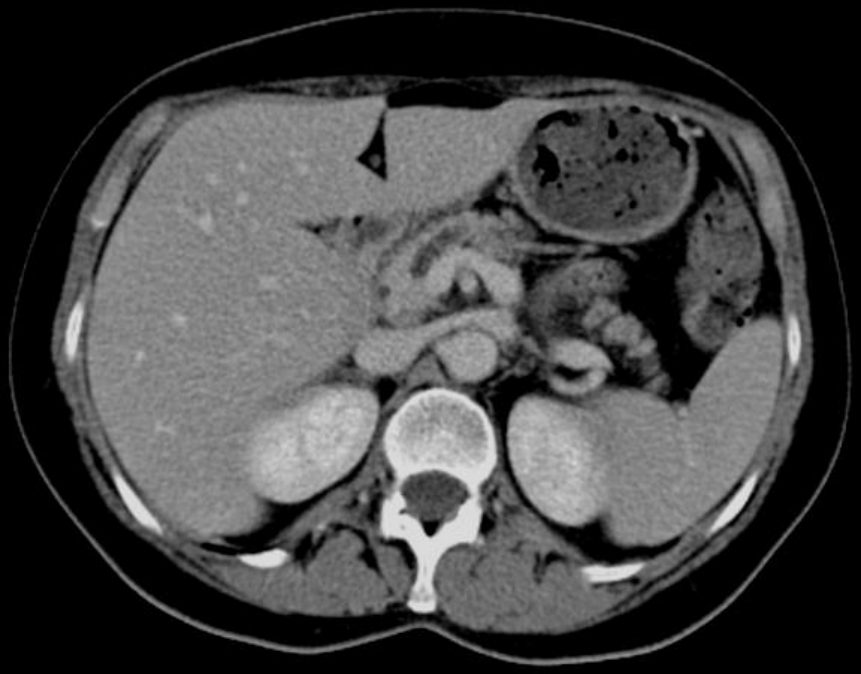

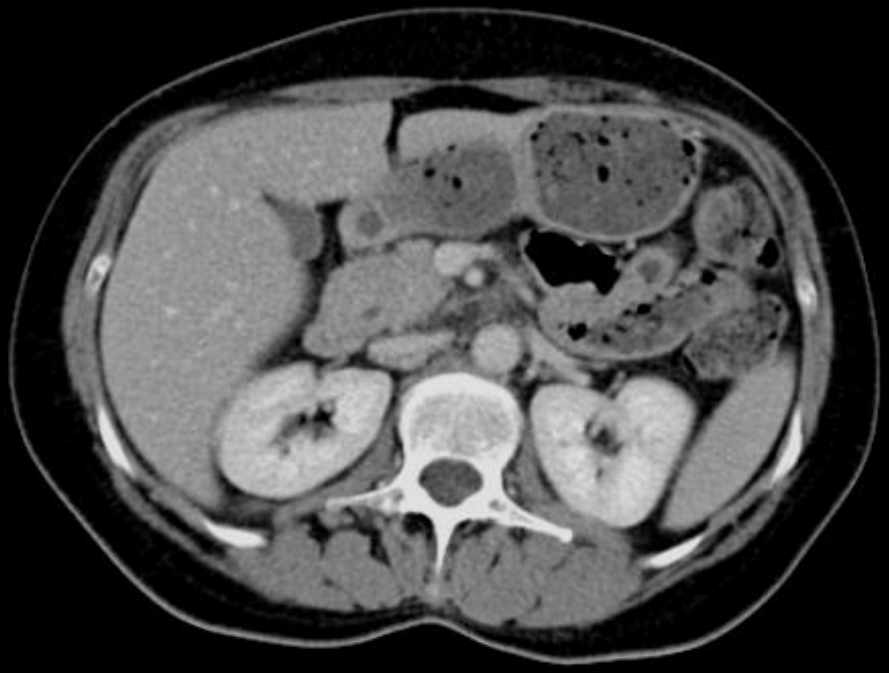

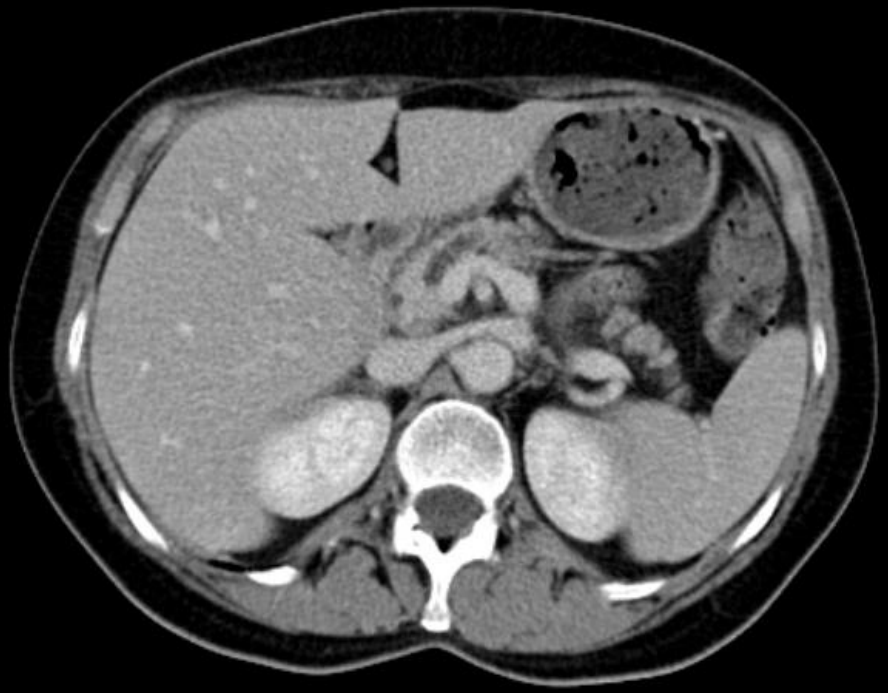

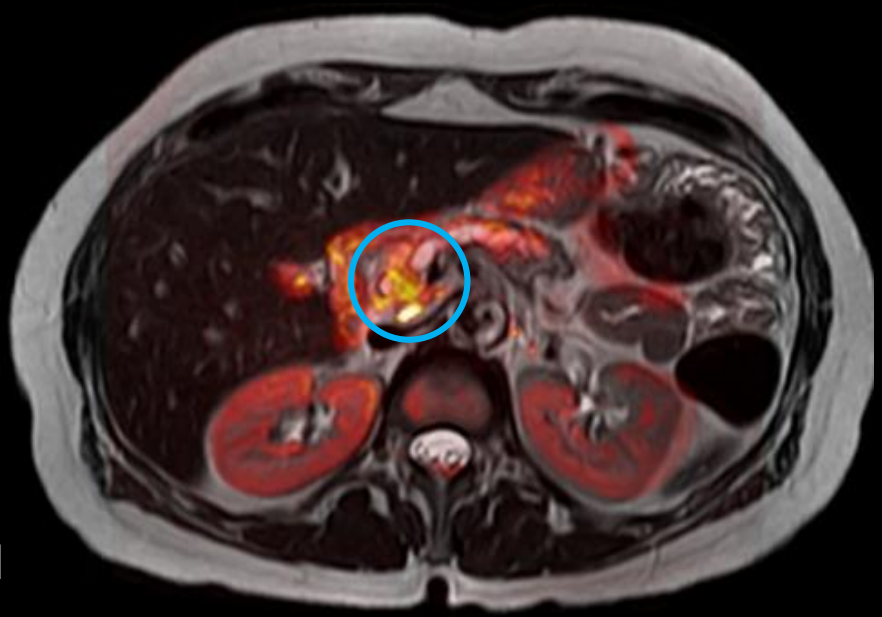

Fusion image T2 + DWI

Completamento RM in caso di TC equivoca

Miglior caratterizzazione tissutale

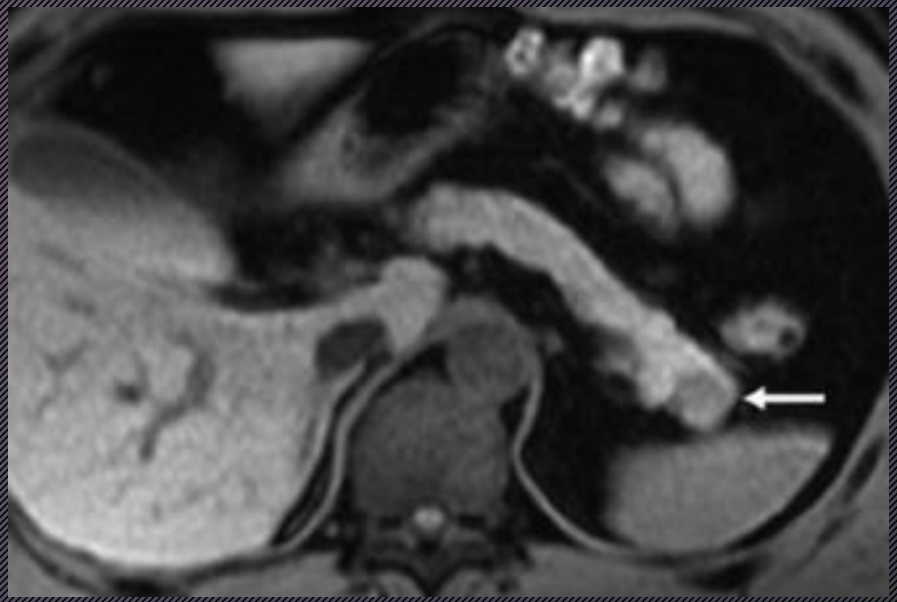

Miglior mapping duttale

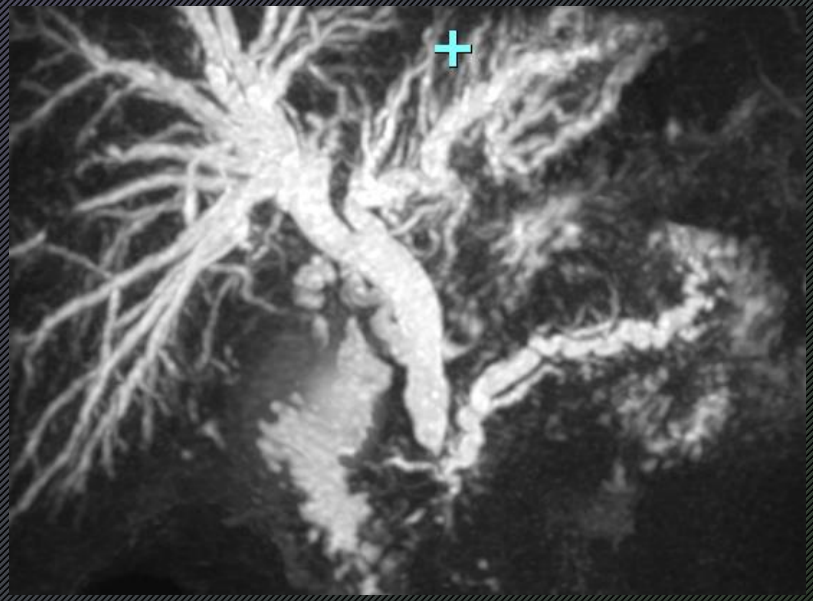

Valutazione RM della lesione

- *Sensibilità: RM+DWI > RM > TC*
- *DWI con alti valori di b (800-1000 s/mm^2)*
  - *Alta risoluzione di contrasto*
  - *Migliore delineazione della massa tumorale*

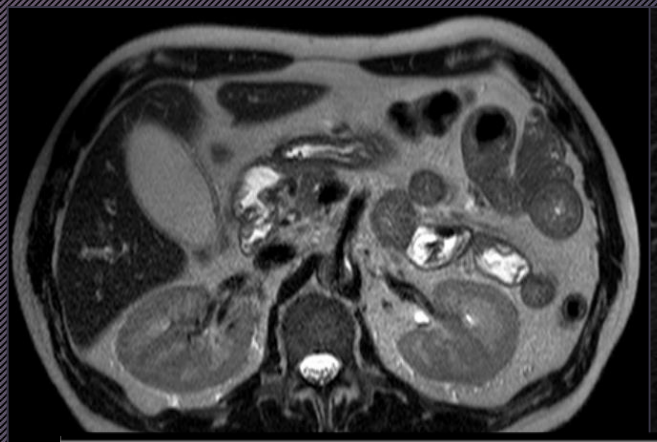

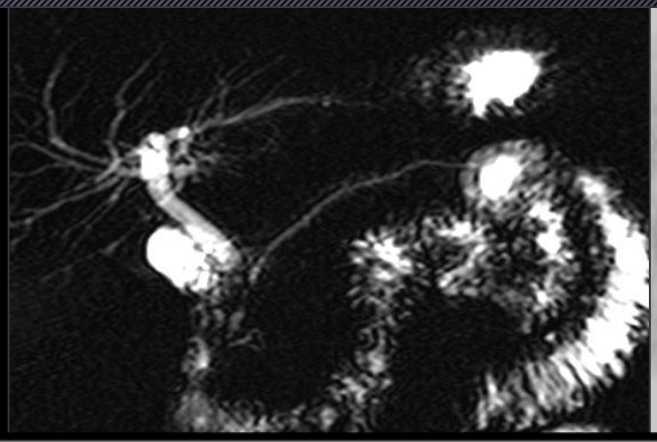

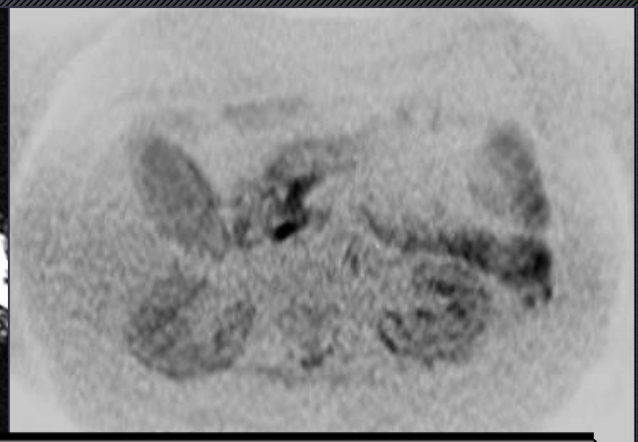

	Conventional MR	PET/CT	DW-MRI
Sensitivity	**80%**	**74%**	**85%**

R

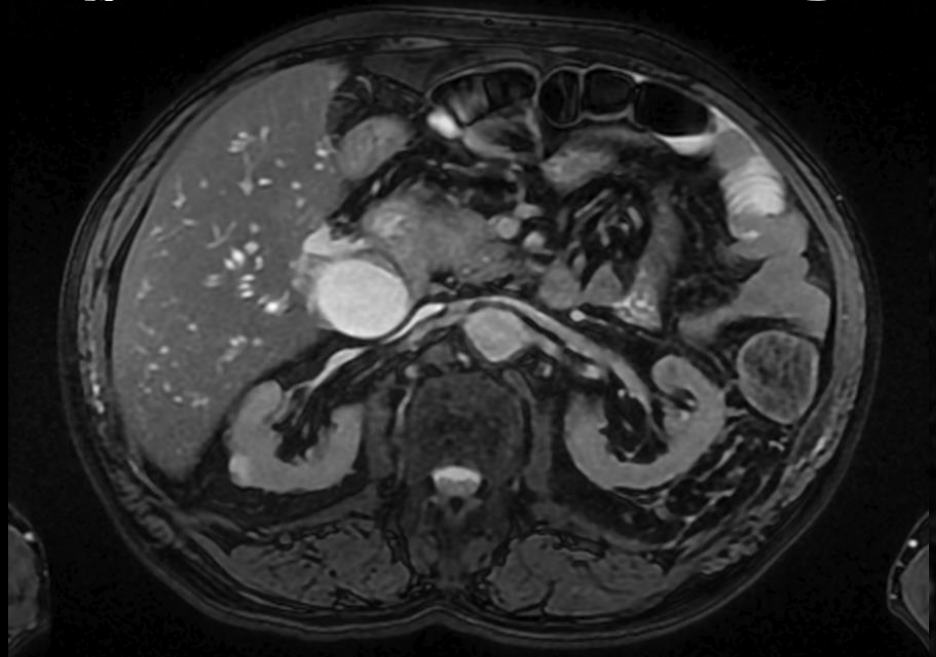

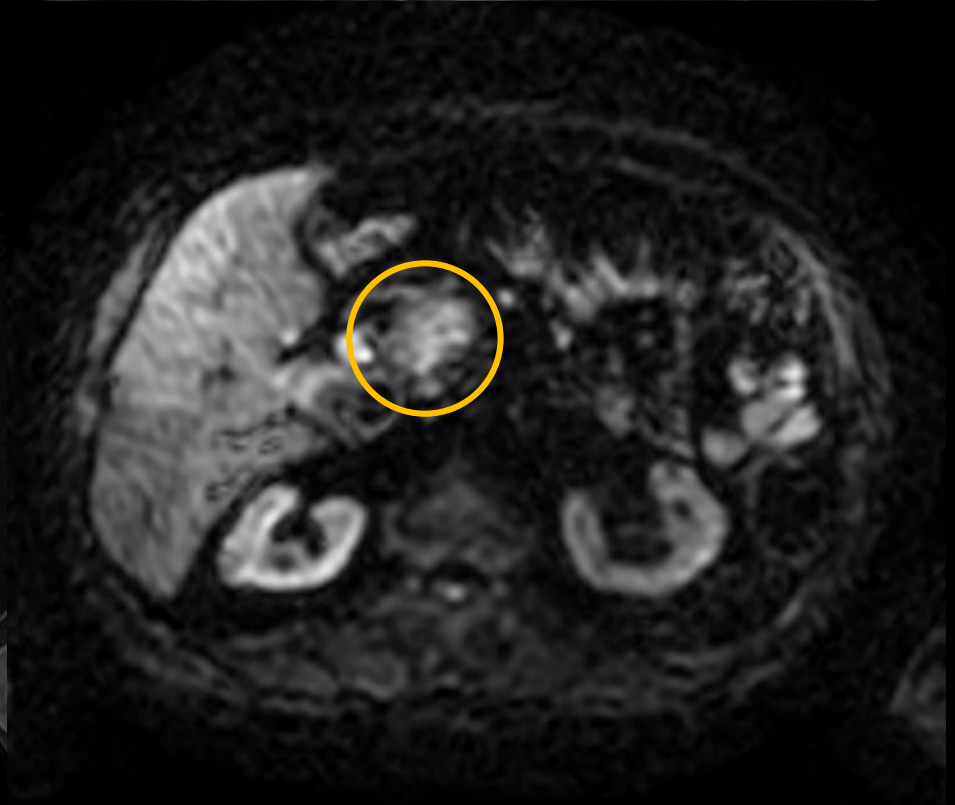

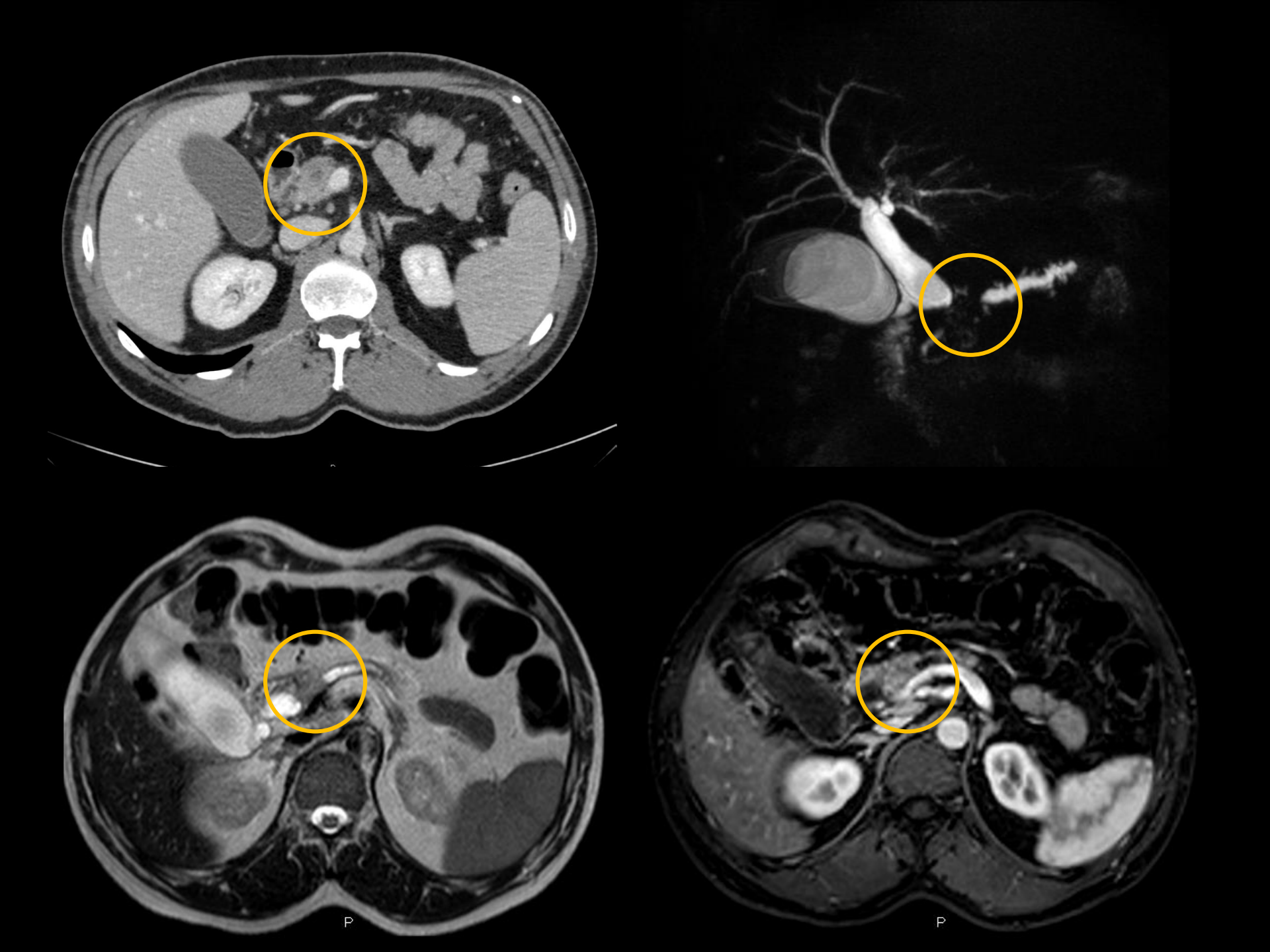
P
P

Indicazioni RM

- *Reperto CT e/o EUS equivoco*
- *Caratterizzazione lesione*
  - *Pancreas*
  - *Lesioni epatiche sincrone*
- *Definizione anatomia albero biliare e Wirsung*

- *Fattori legati al paziente*
  - *Insufficienza renale*
  - *Allergia al MDC iodato*

Caratterizzazione

- Lesioni solide
  - Maligne
  - Benigne
- Lesioni cistiche
  - Uniloculari semplici
  - Microcistiche
  - Settate o “complesse”
- Solide con componenti cistiche

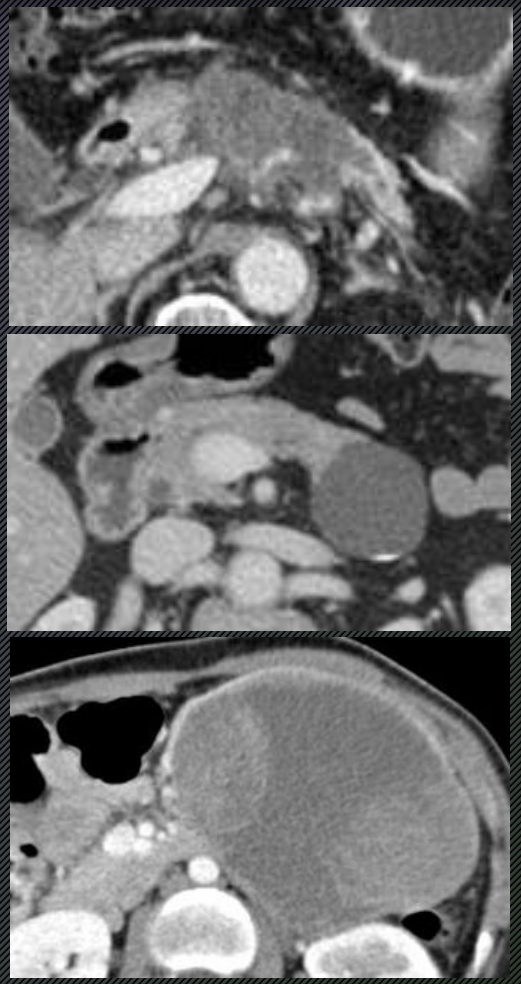

Caratterizzazione

Pattern ipervascolare

Pattern cistico

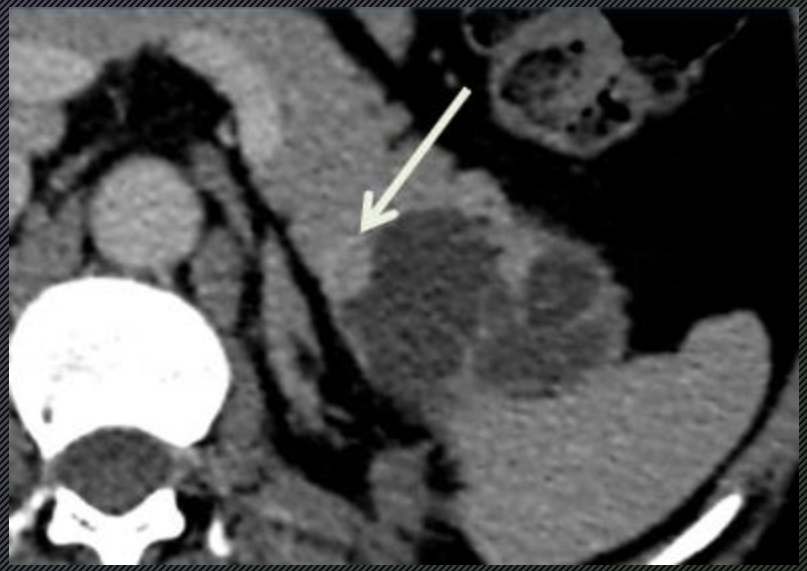

- *Pseudocyst,*
- *IPMN,*
- *Serous cystadenoma*
- *Epithelial cysts*

- *Serous Cystadenoma*

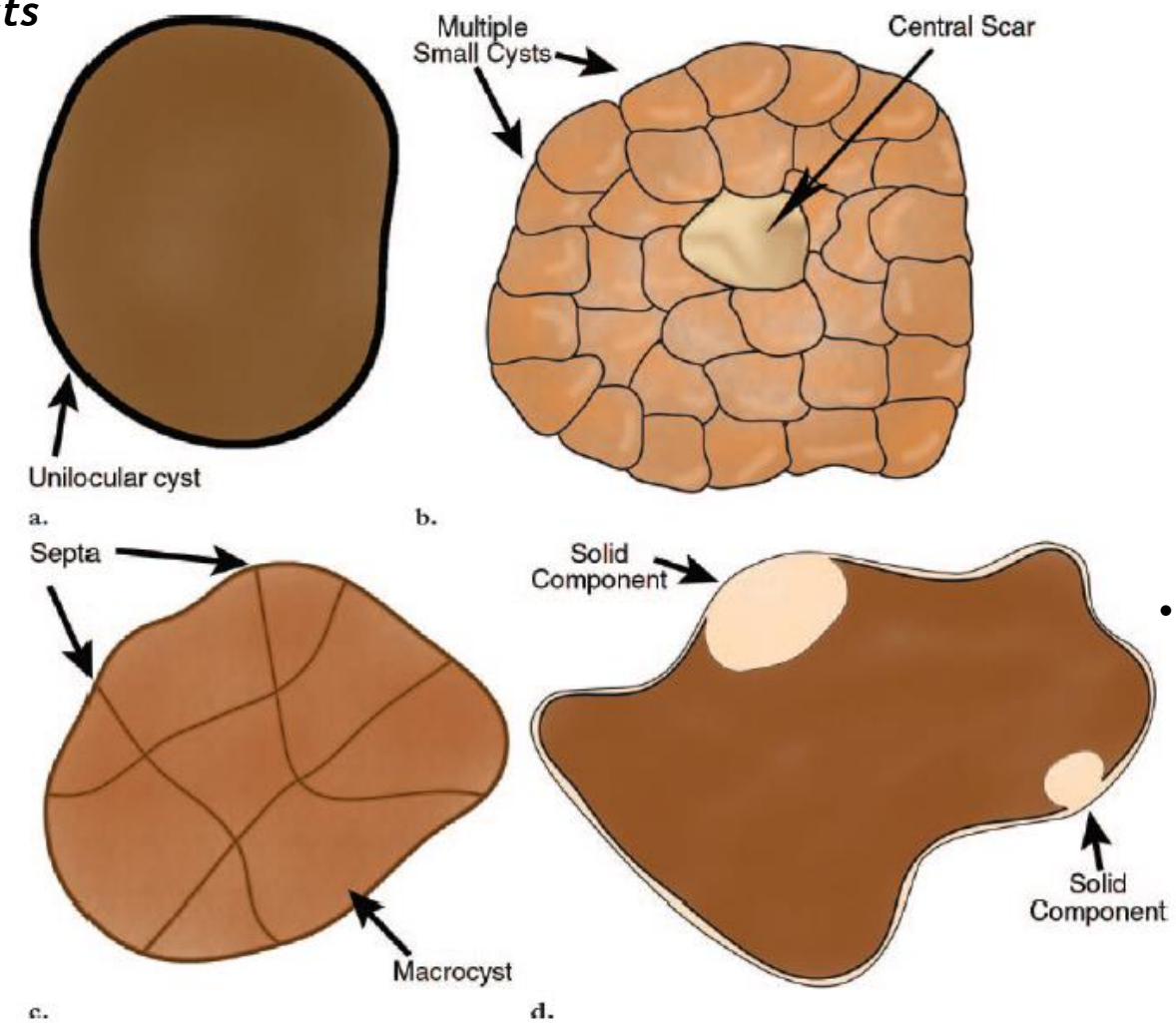

- *Mucinous cystic neoplasm*
  - *IPMN*
  - *AdenoCa*
  - *Solid pseudopapillary tumour*
  - *NET*
  - *Mets*
  - *Sarcoma*
- *Cystic teratoma*

- *Mucinous cyst adenoma*
- *IPMN*

Intraductal papillary mucinous neoplasms (IPMN)

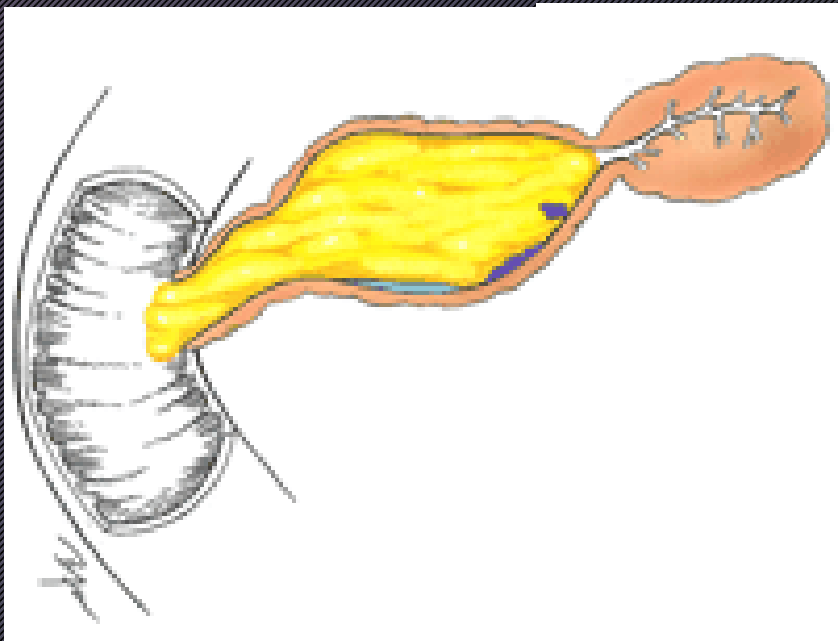

Characterized by papillary proliferation of pancreatic ductal epithelium & production of mucin

3 Types:

Main duct (70% chance of malignancy)

Branch duct (20% chance of malignancy)

Mixed

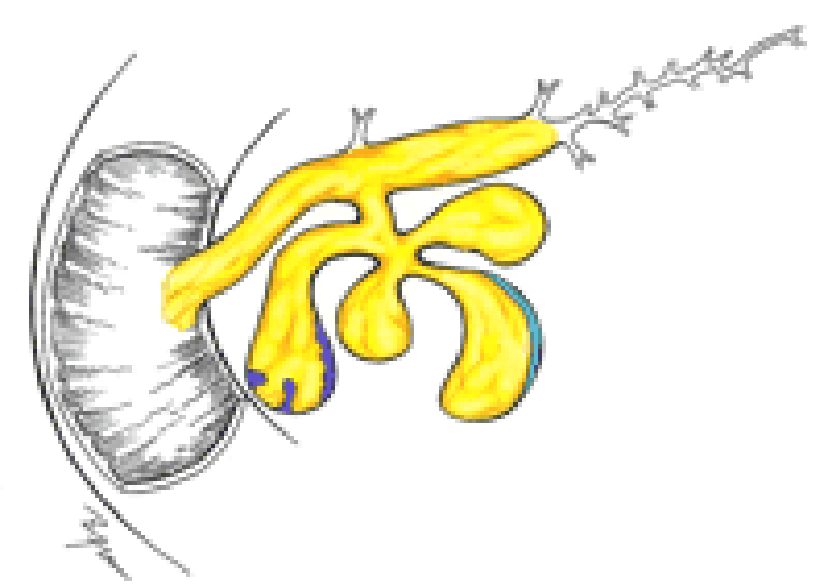

Morphologic classification of IPMN

Branch pancreatic duct

Diffuse main pancreatic duct

Segmental main pancreatic duct

Mixed (main & branch ducts)

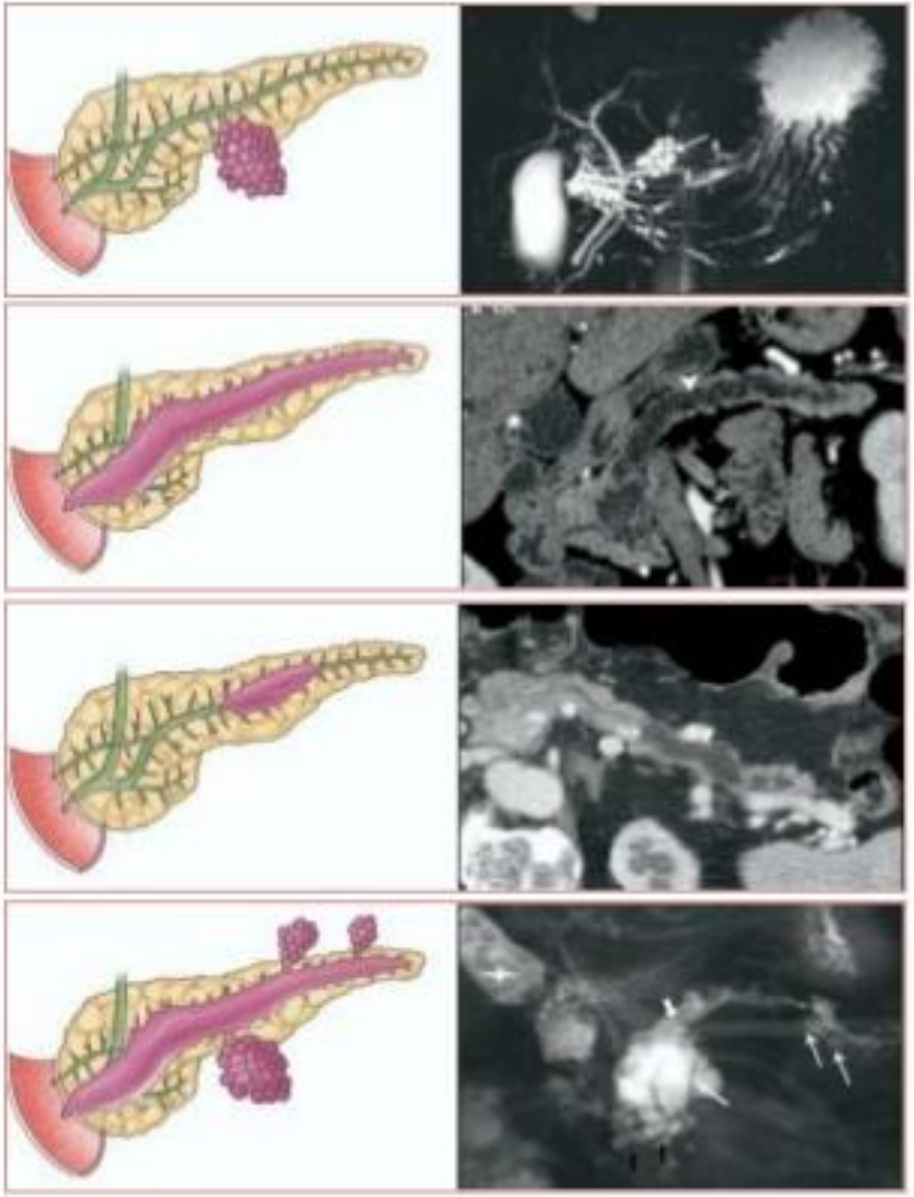

Sahani DV et al. Clin Gastroenterol Hepatol 2009; 7 : 259 – 269.

Staging TNM

T1	Tumor ≤ 2 cm
T1a	Tumor ≤ 0.5 cm
T1b	Tumor > 0.5 cm and < 1cm
T1c	Tumour 1-2 cm
T2	Tumor > 2 cm < 4 cm
T3	Tumor > 4 cm
T4	Tumor with vascular involvement
N0	No regional lymph node metastasis
N1	Metastasis in 1 to 3 regional lymph nodes
N2	Metastasis in 4 or more regional lymph nodes
M0	No distant metastasis
M1	Distant metastasis

AJCC 8th Ed. 2017

Staging tumorale

- TC con mdc / RM con mdc +/- Colangio RM
  - Diagnosi e staging
- Ecoendoscopia: complementare alla TC/RM
  - Biopsia
  - Coinvolgimento Vascolare
  - Coinvolgimento Linfonodale
- TC-PET: non indicata nello staging loco-regionale
  - Pazienti ad alto rischio -> Metastasi a distanza

Stadiazione

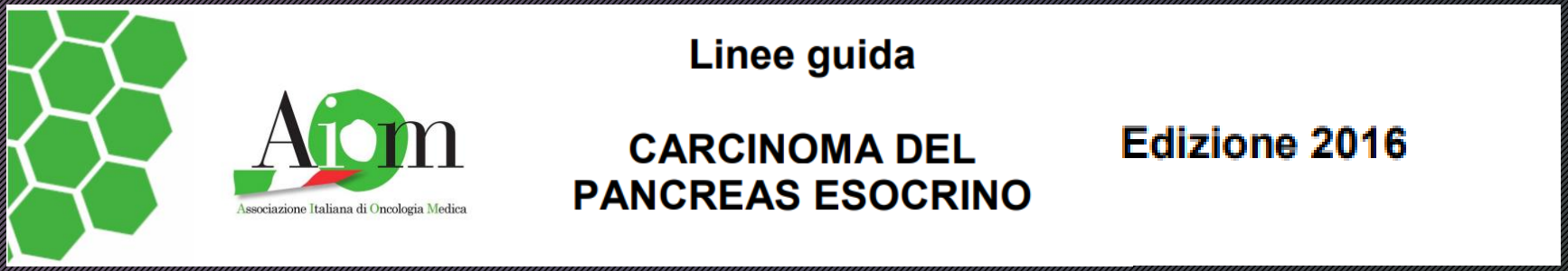

- *TC Torace-addome con mdc: Esame di scelta per stadiazione (livello di evidenza IV)*
- *Accuratezza nel definire resecabilità: 70-85*

Stadiazione – *contributo TC*

1. *Dimensioni e sede del tumore*
2. *Coinvolgimento dei vasi*
3. *Coinvolgimento dei linfonodi*
4. *Metastasi*
5. *Varianti anatomiche*

Stadiazione/Resecabilità

*Se non ci sono metastasi, il giudizio di **resecabilità** si basa in gran parte sul rapporto del tumore con i **grossi vasi***

Fondamentale:

presenza e grado di contatto
tra il tumore e i vasi peri-pancreatici

Stratificazione del paziente: flowchart

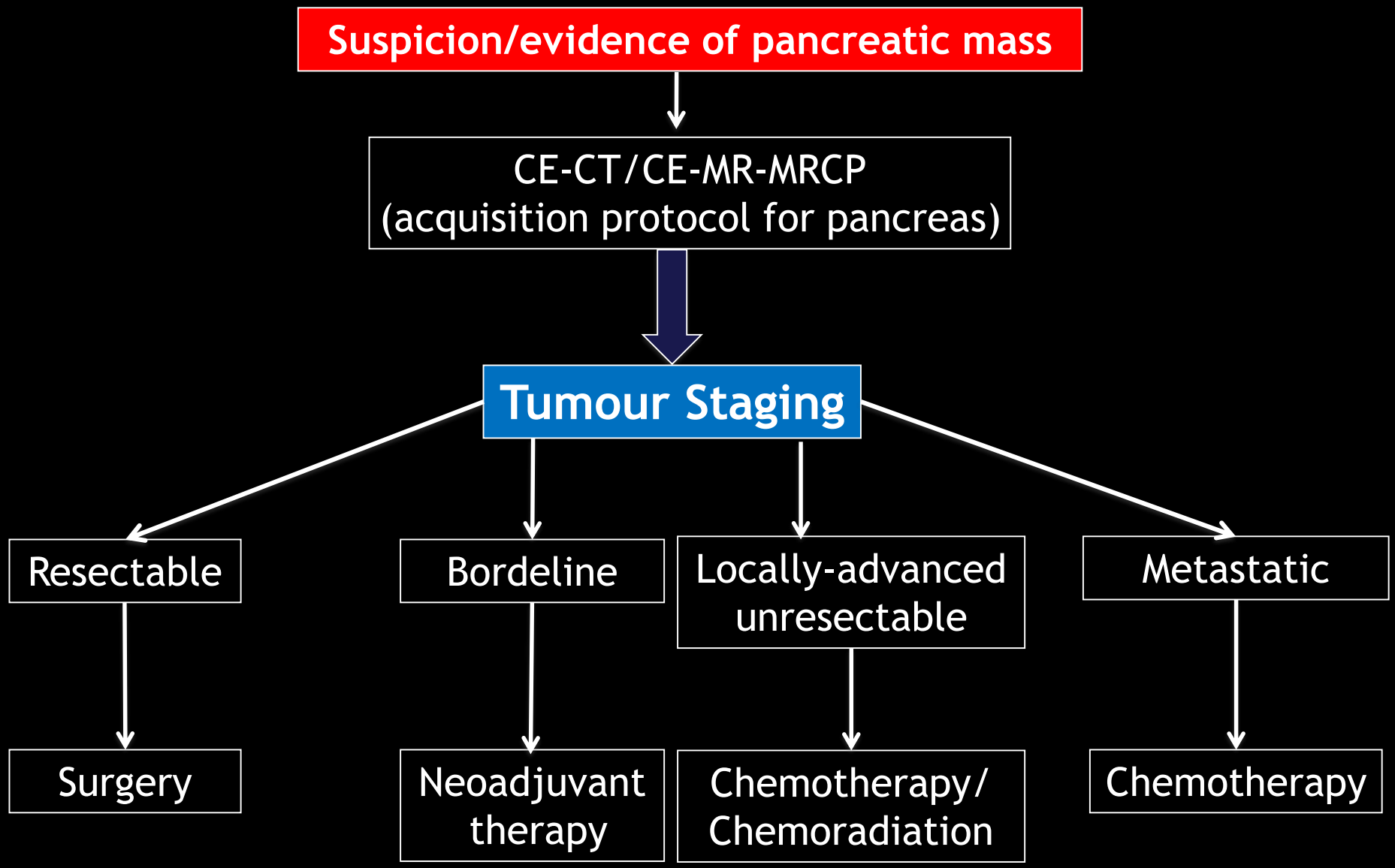

NCCN guidelines Version 3.2017

TC: determinare la resecabilità

Meglio se casi discussi da un TEAM MULTIDISCIPLINARE

INFILTRAZIONE ARTERIOSA: Quando?

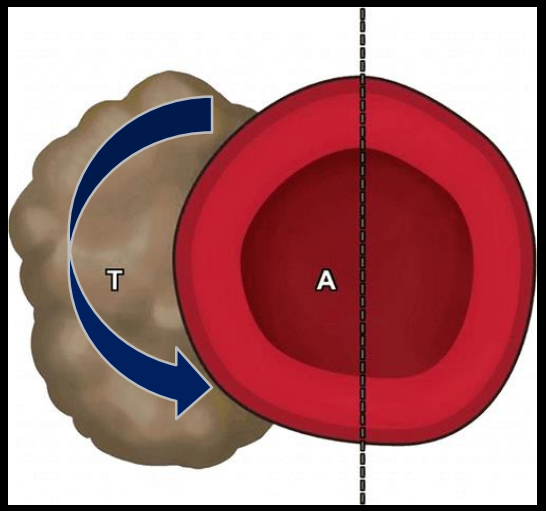

< 180°

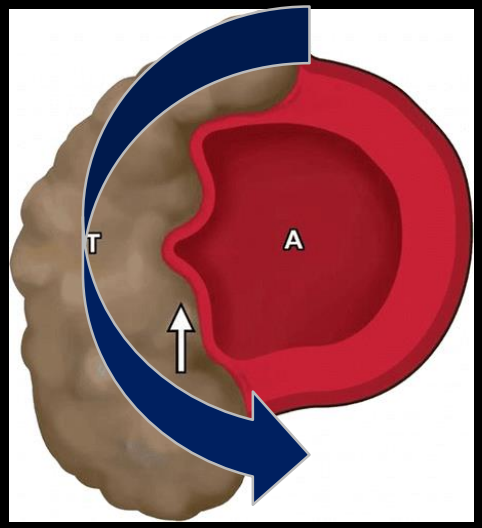

180°

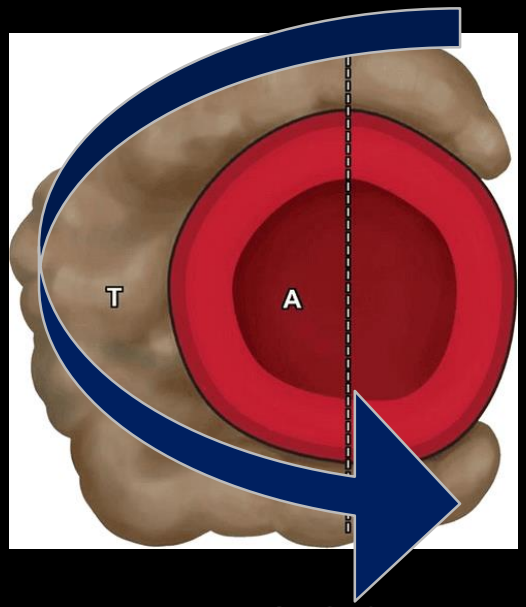

> 180°

- Modificazioni del calibro, irregolarità del contorno
- Coinvolgimento dei primi rami della AMS (a. digiunali, a. coliche)
- Coinvolgimento dell'a. epatica comune (la DX o la SN si possono sacrificare)
- Estensione al tripode

Infiltrazione completa SMA

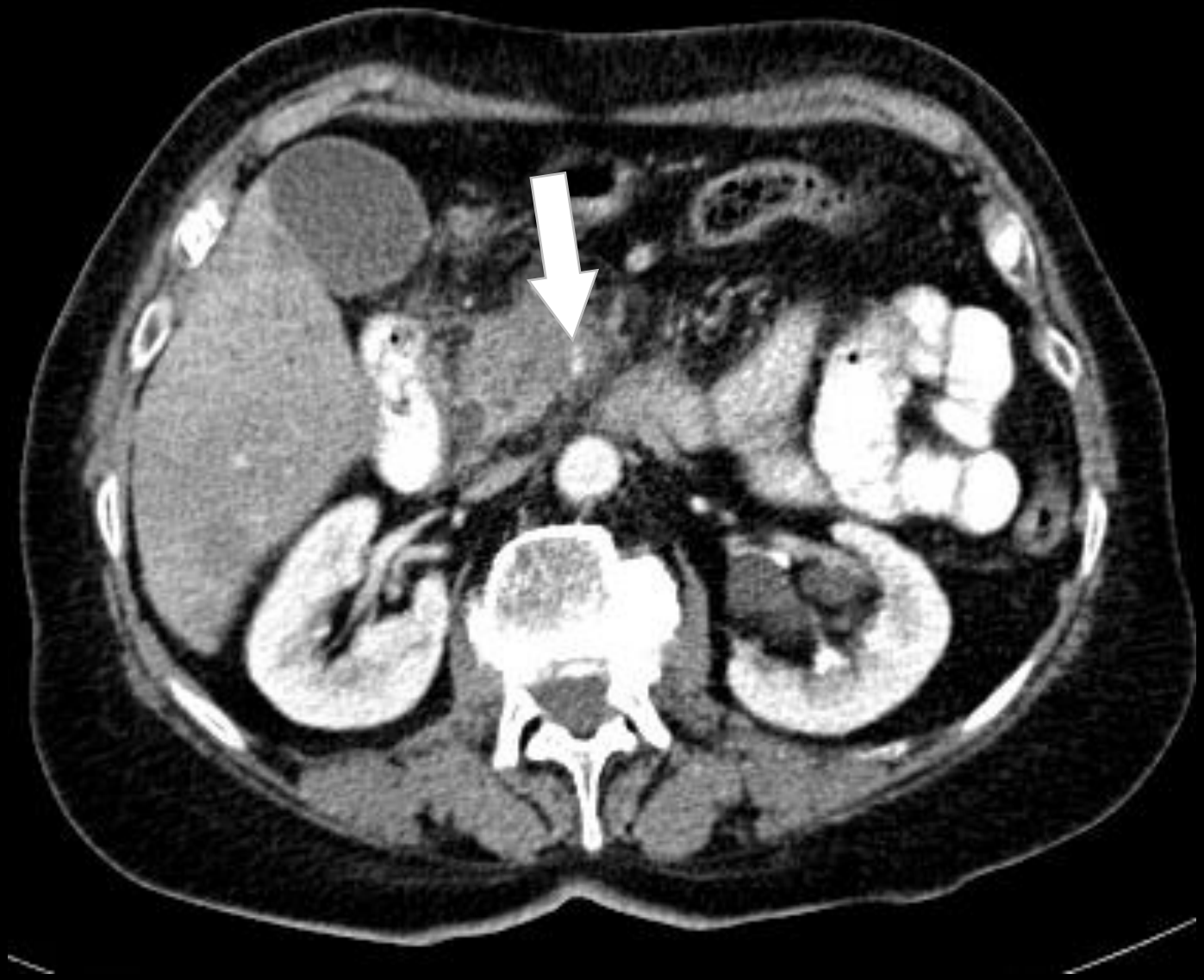

INFILTRAZIONE VENOSA: Quando ?

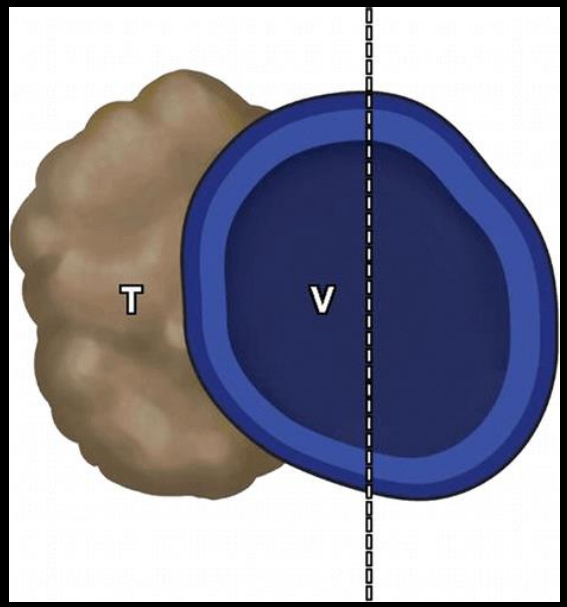

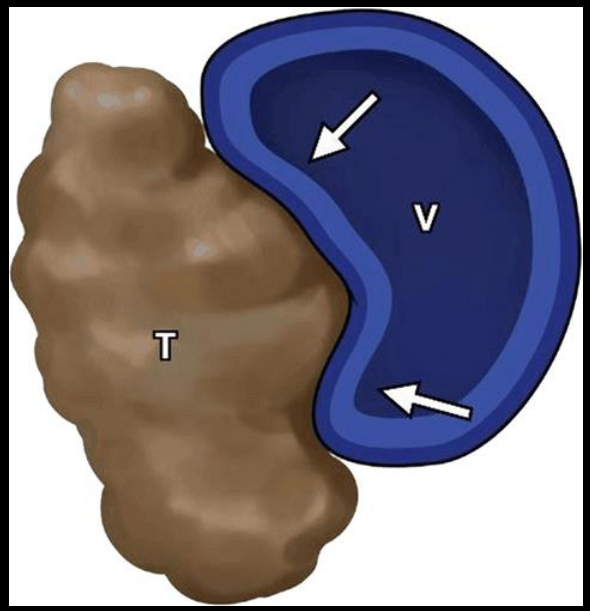

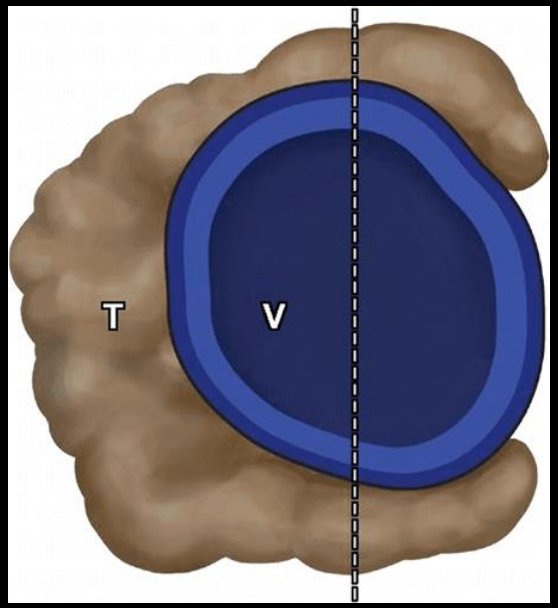

Infiltrazione < o > 180°

Trombosi

Stenosi

Irregolarità del contorno

v. Porta

VMS

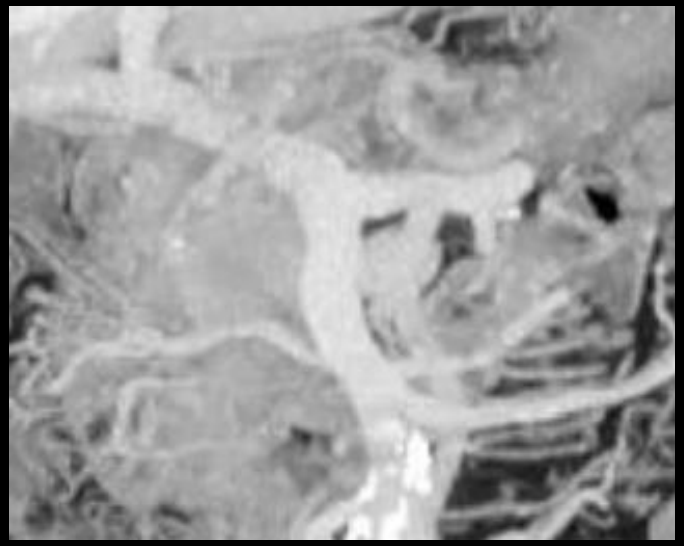

No invasione della PV/VMS

Stenosi unilaterale

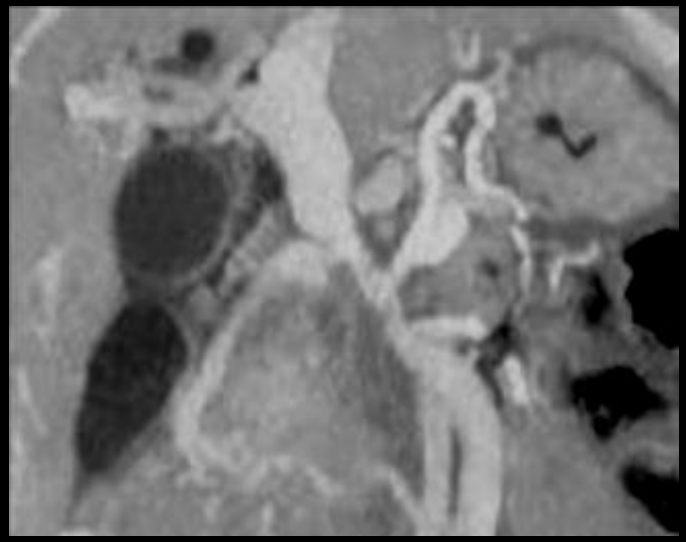

Stenosi bilaterale

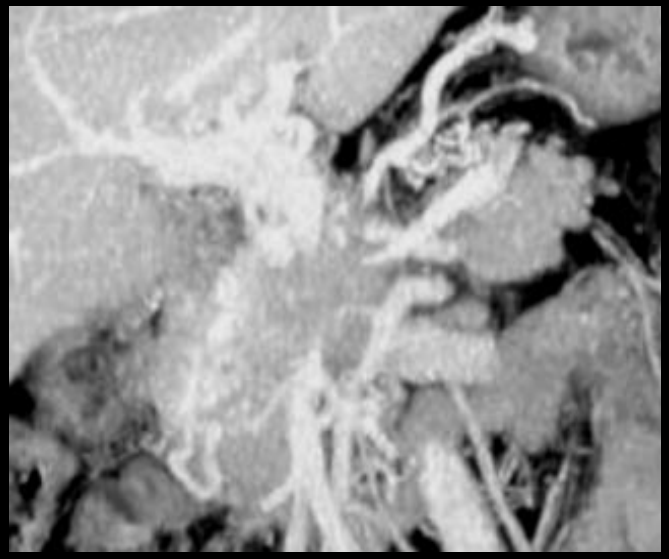

Ostruzione con collaterali

Malattia resecabile

Assenza di contatto tumorale o stenosi unilaterale della SMV/PV

Assenza di contatto tumorale con SMA, CA, CHA

Malattia “borderline resectable”

Tumori potenzialmente resecabili con rapporto “borderline” fra tumore e vasi

Distinzione fra infiltrazione venosa/arteriosa

Distinzione in sottoclassi in base al grado di estensione dell’infiltrazione vascolare venosa

Contents lists available at ScienceDirect

Pancreatology

journal homepage: www.elsevier.com/locate/pan

International consensus on definition and criteria of borderline resectable pancreatic ductal adenocarcinoma 2017

Shuji Isaji [a,*], Shugo Mizuno [a], John A. Windsor [b], Claudio Bassi [c], Carlos Fernandez-del Castillo [d], Thilo Hackert [e], Aoi Hayasaki [a], Matthew H.G. Katz [f], Sun-Whe Kim [g], Masashi Kishiwada [a], Hirohisa Kitagawa [h], Christoph W. Michalski [e], Christopher L. Wolfgang [i]

[a] *Hepatobiliary-Pancreatic and Transplant Surgery, Mie University Graduate School of Medicine, Japan*
[b] *HBP/Upper GI Unit, Auckland City Hospital/Department of Surgery, University of Auckland, New Zealand*
[c] *Pancreas Surgery Unit, Pancreas Institute, Verona University Hospital, Verona, Italy*
[d] *Department of General and Gastrointestinal Surgery, Massachusetts General Hospital/Harvard Medical School, USA*
[e] *Department of Surgery, University of Heidelberg, Germany*
[f] *Department of Surgical Oncology, Division of Surgery, The University of Texas MD Anderson Cancer Center, USA*
[g] *Department of Surgery, Seoul National University Hospital, South Korea*



Malattia "borderline resectable"



BR-PV (SMV/PV involvement alone)

- *SMV/PV: tumor contact 180° or greater*
- *Bilateral narrowing/occlusion SMV, not exceeding the inferior border of the duodenum*
- *SMA, CA, CHA: no tumor contact/invasion*

Malattia "borderline resectable"



BR-A (arterial involvement)

- *SMA, CA: tumor contact < 180° without showing deformity/stenosis*

- *CHA: tumor contact without showing tumor contact of the PHA and/or CA (involvement of the aorta is categorized as unresectable)*

- *Presence of variant arterial anatomy is not taken into consideration*

SB bordo superiore duodeno

MB terzo medio duodeno

IB bordo inferiore duodeno

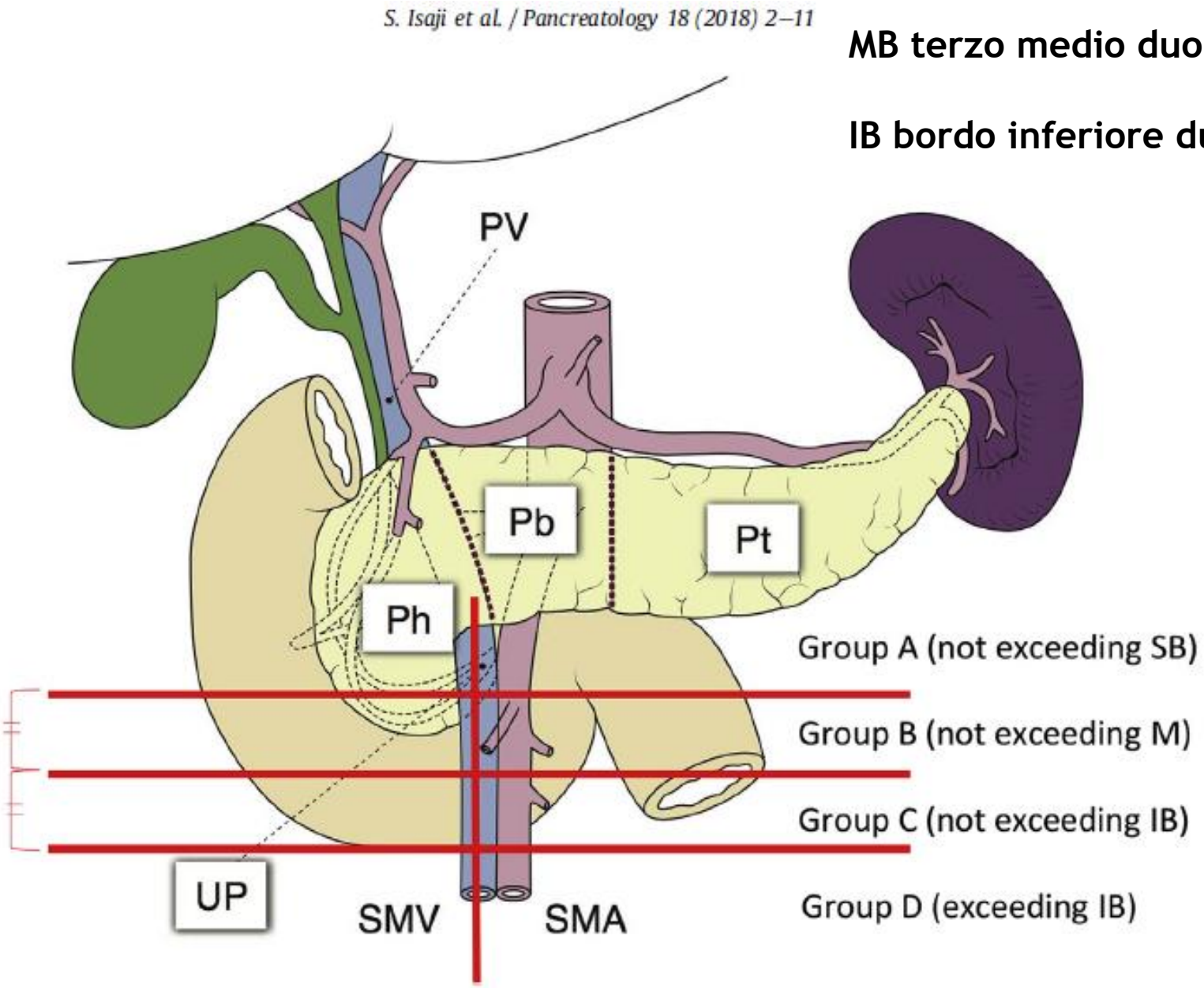

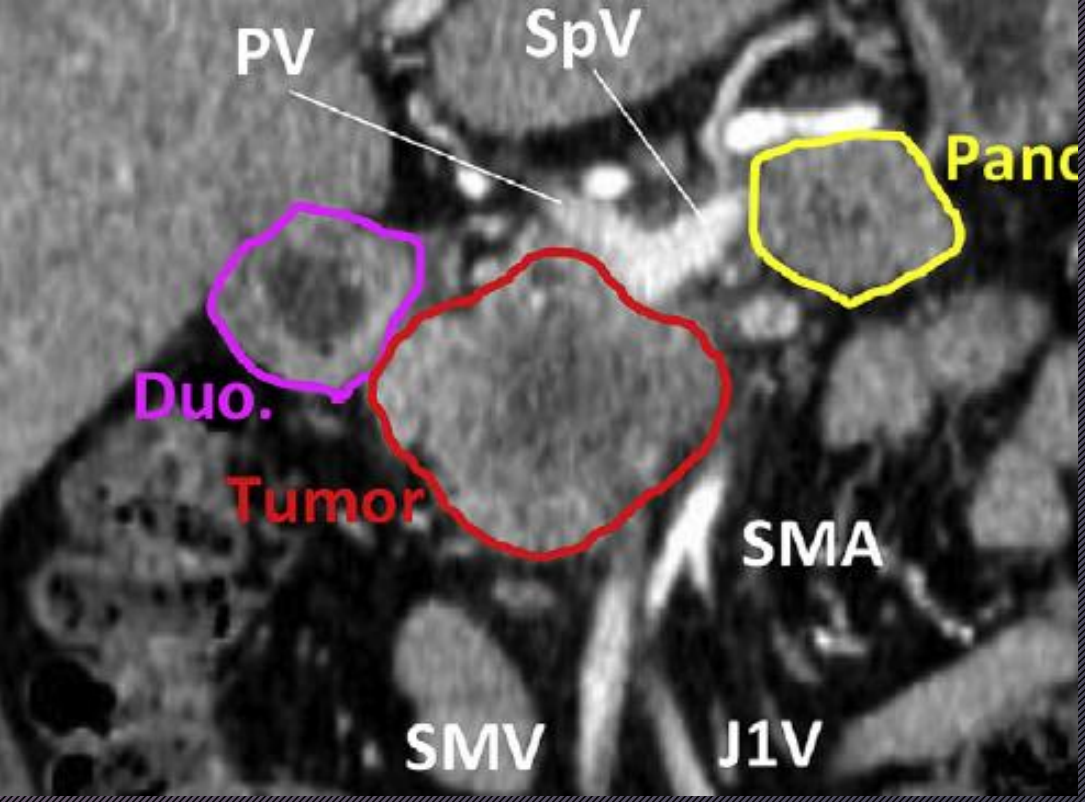

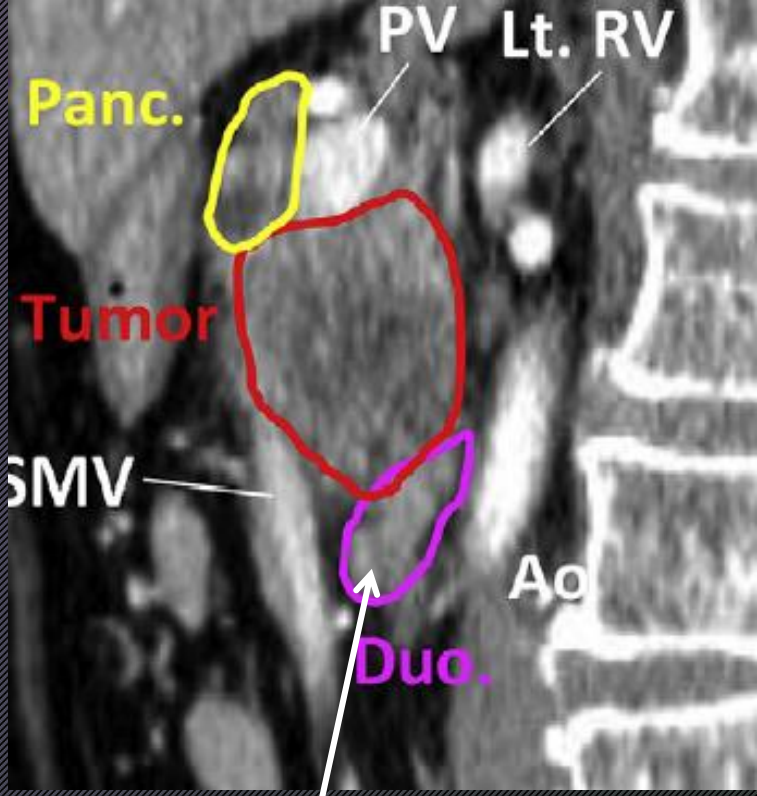

Borderline Resectable

Il Tumore cefalopancreatico invade la SMV/PV, ma non si estende oltre il bordo inferiore del duodeno

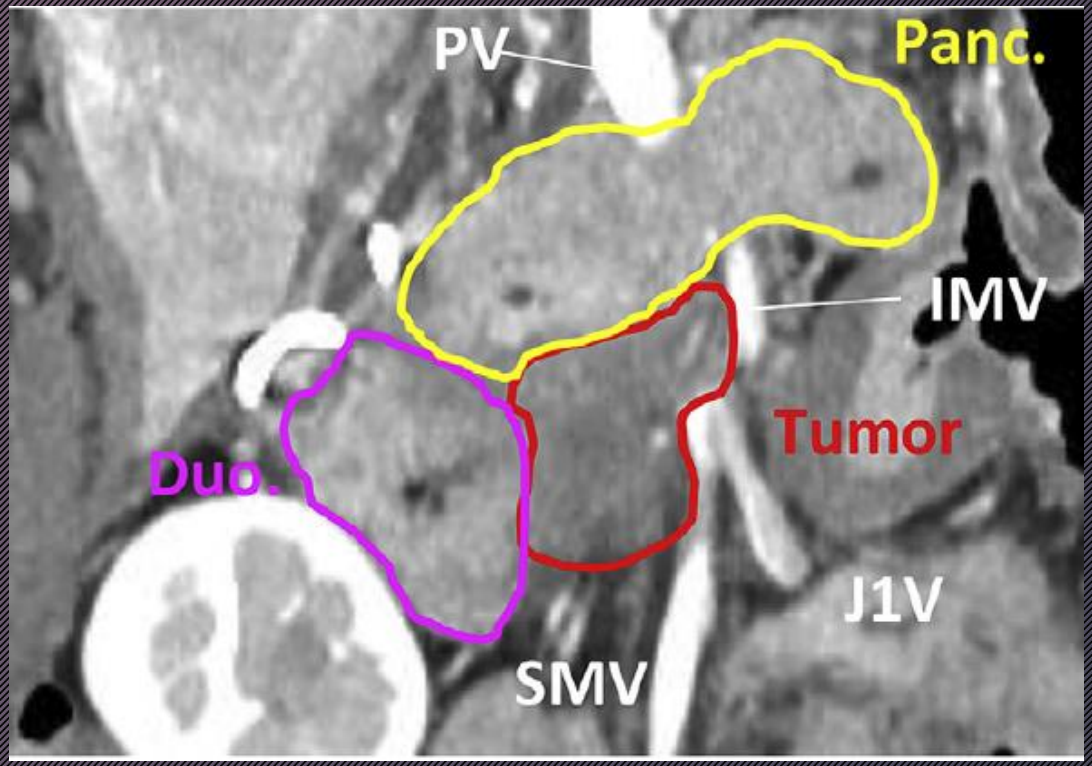

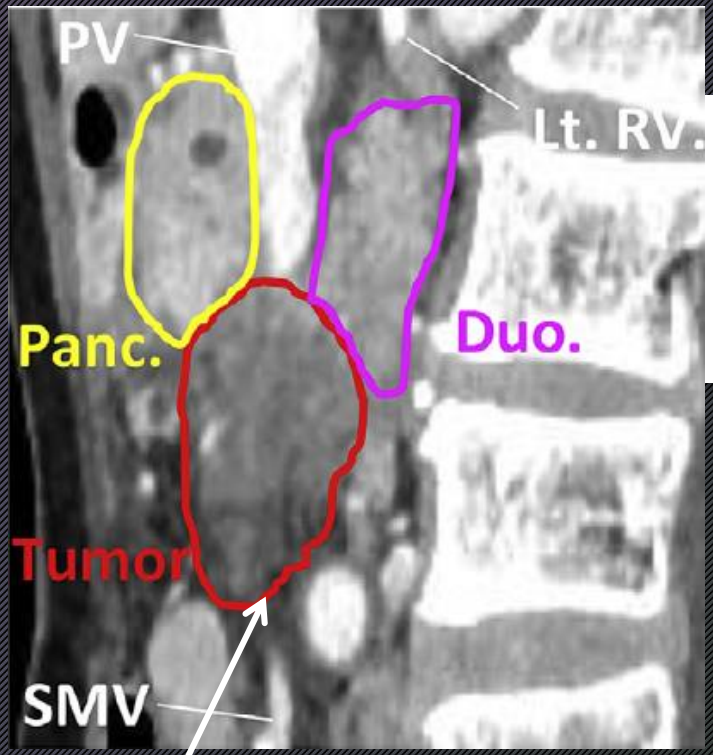

Tumore non resecabile

Il Tumore invade la SMV/PV ma si estende oltre il bordo inferiore del duodeno

Malattia non resecabile

Criteri di non resecabilità uniformemente accettati :

- Metastasi a distanza
(fegato, peritoneo, polmone/pleura ecc)
- Metastasi linfonodali in stazioni distanti dal campo chirurgico
(Linfonodi interaortocavali o periaortici, mediastinici o sovraclaveari)
- Infiltrazione dei visceri extrapancreatici…

…ad eccezione di VBP e duodeno

Criticità dell'imaging

TNM accurato?

Infiltrazione vascolare

Microspread

N+

Seeding peritoneale
Invasione neurale

L'adenocarcinoma pancreatico

invade localmente per:

1. *Estensione diretta*
2. *Invasione linfatica*
3. *Invasione perineurale*

Pathways of Extrapancreatic Perineural Invasion by Pancreatic Adenocarcinoma: Evaluation With 3D Volume-Rendered MDCT Imaging

Swati D. Deshmukh[1]
Jürgen K. Willmann
R. Brooke Jeffrey

OBJECTIVE. The purpose of this article is to familiarize radiologists with the common pathways of extrapancreatic perineural invasion of pancreatic adenocarcinoma and to highlight the potential value of 3D volume-rendered MDCT in its diagnosis.

CONCLUSION. The perineural plexuses closely follow peripancreatic vessels, which

Criticità Imaging

Le tre modalità non sono distinguibili alla TC
l'invasione perineurale è una modalità molto frequente (neurotropismo del tumore)

E' spesso causa di recidiva dopo intervento e di margini chir. positivi
Non vi è correlazione con la dimensione del tumore (anche in tumori < 2 cm)

Può essere sospettata quando ***tessuto sfumato si estende lungo i plessi NERVOSI peripancreatici.***

Criticità Imaging
- invasione perineurale -

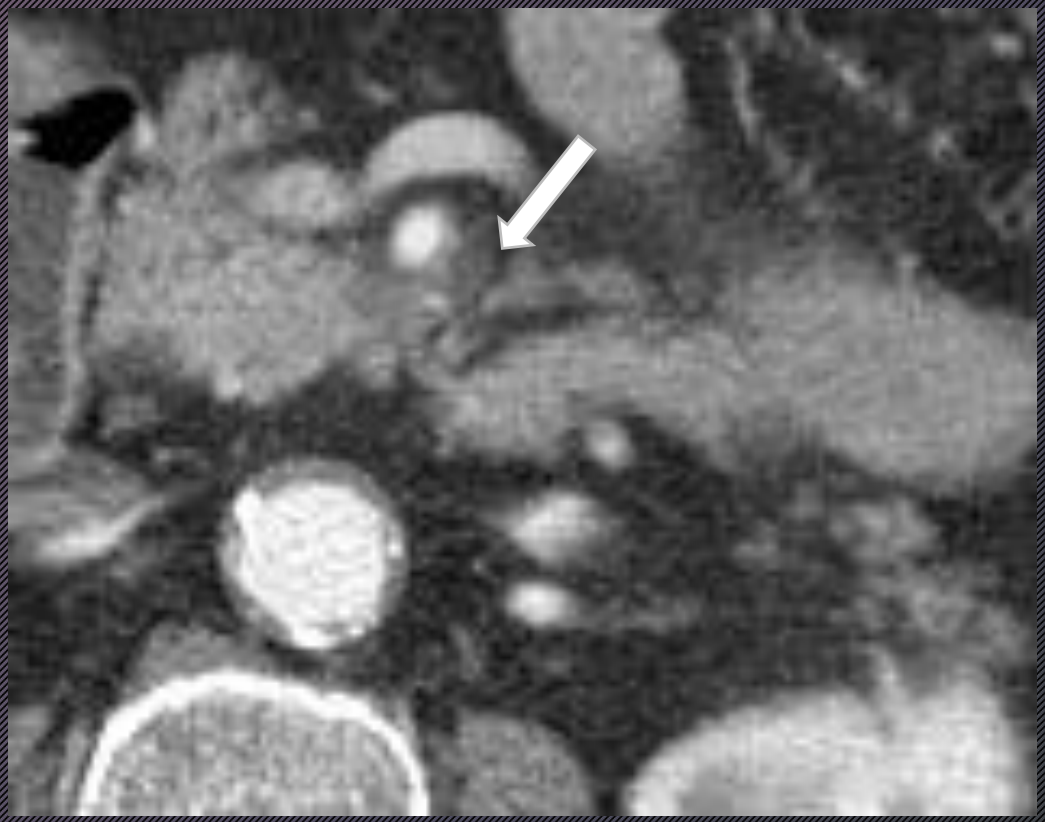

*Può essere sospettata quando **tessuto sfumato si estende lungo i plessi NERVOSI peripancreatici.***

Criticità Imaging
- invasione linfatica -



Il cancro del pancreas ha meta linfonodali nel 70% dei casi

Presenza e localizzazione TC di linfonodi sospetti:

- *Asse corto >1 cm*
- *Rotondeggianti*
- *Disomogenei*
- *Necrosi centrale*

Limiti TC nell'individuare le metastasi linfonodali < 1cm

Criticità Imaging
- invasione linfatica -

4 categorie di linfonodi locoregionali:

1. *Sovra-pancreatici sopra il corpo e testa pancreatici*
2. *Anteriori, incluso i pancreatico-duodenali, mesenterici prossimali, pilorici*
3. *Infrapancreatici sotto la testa/corpo pancreatici*
4. *Posteriori , incluso i pancreatico-duodenali posteriori, lungo il dotto biliare principale e i mesenterici prossimali*

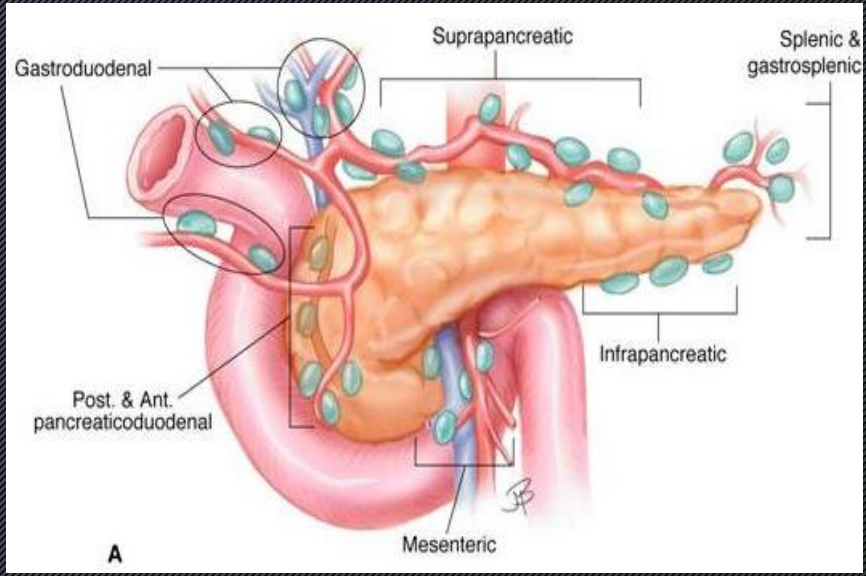

La descrizione TC dei linfonodi loco-regionali lascia il tempo che trova, in quanto…
IL CHIRURGO ASPORTA TUTTI QUELLI CHE PUO' !

Criticità Imaging
- invasione linfatica -

ATTENZIONE AI LINFONODI LONTANI: SONO VERE METASTASI (M+)

(con i limiti di specificità/sensibilità della TC)

Follow-up - Restaging

Dopo Terapia neoadiuvante

- *Difficile distinguere fra tessuto tumorale necrotico e vitale*
- *Difficile discriminare fra fibrosi post-attinica e residuo tumorale*

Stable disease: indice surrogato di riposta..

Re-staging post chemioterapia neo-adiuvante

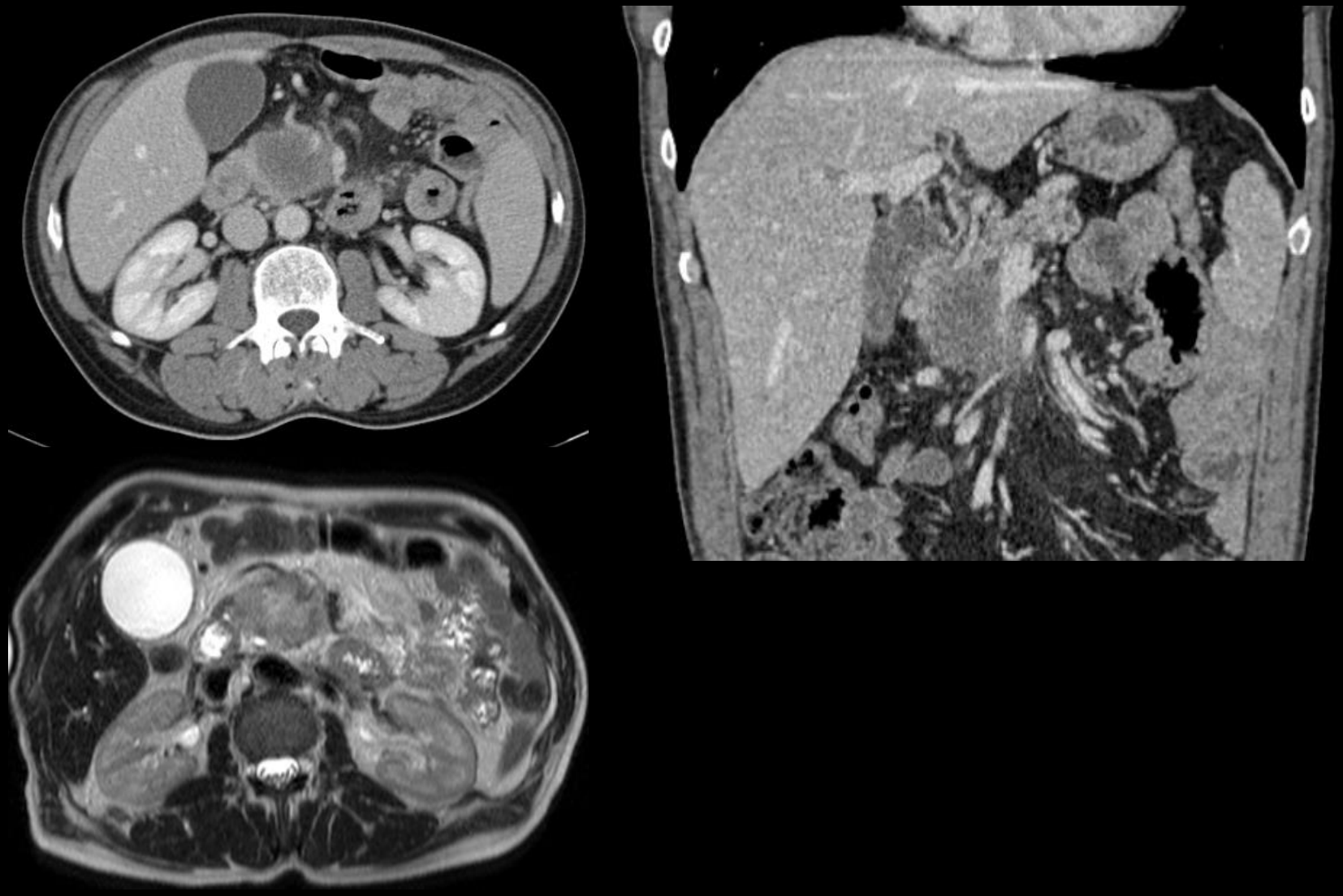

Re-staging post chemioterapia neo-adiuvante

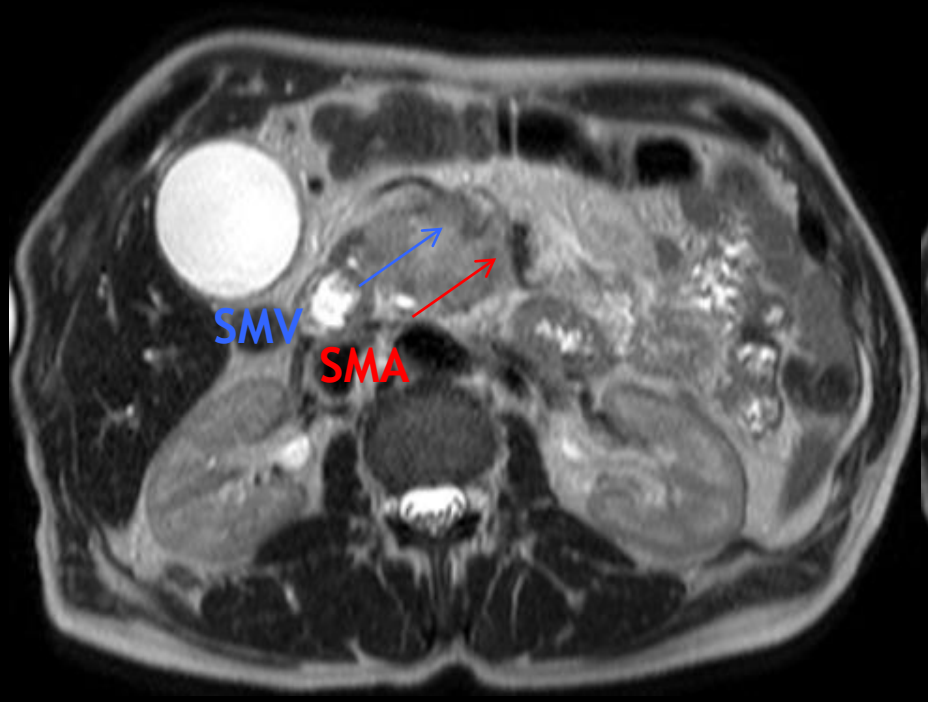

Baseline

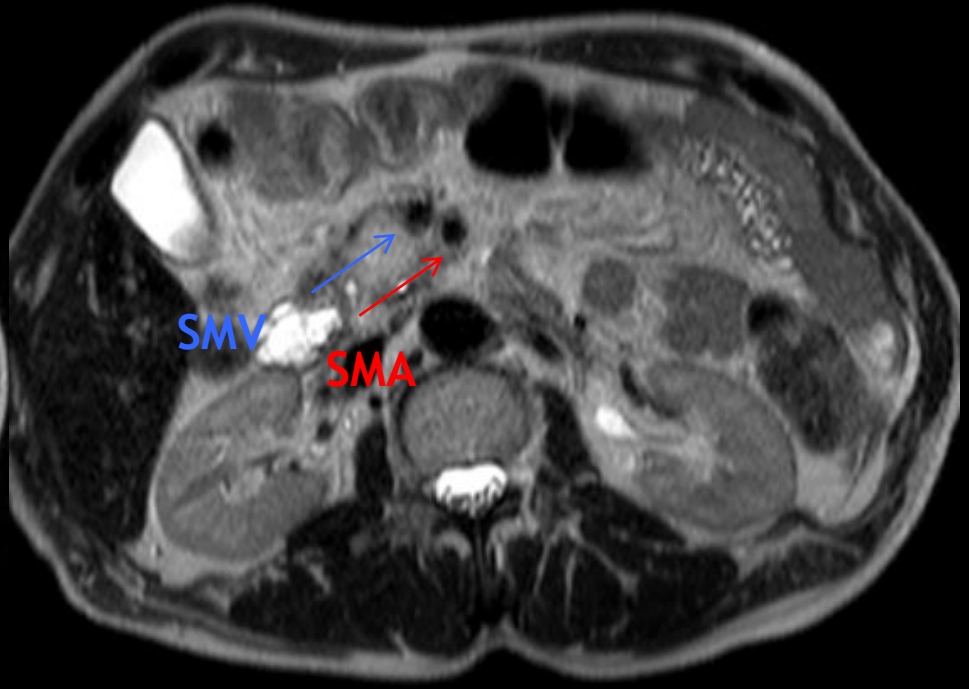

Fine terapia neo-adiuvante

Trend futuri? - Radiomics!

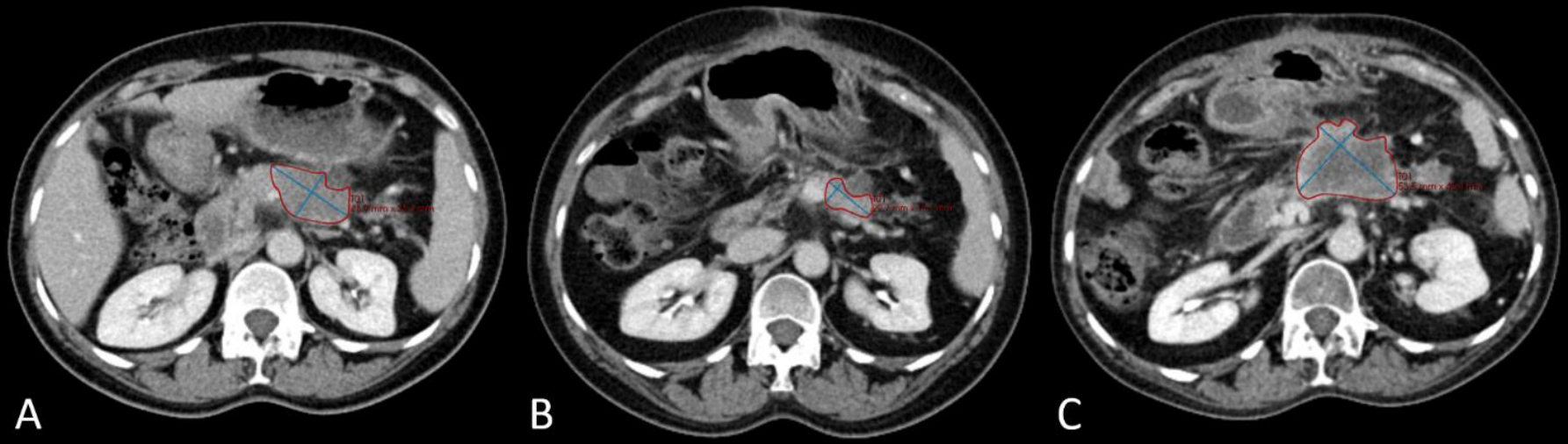

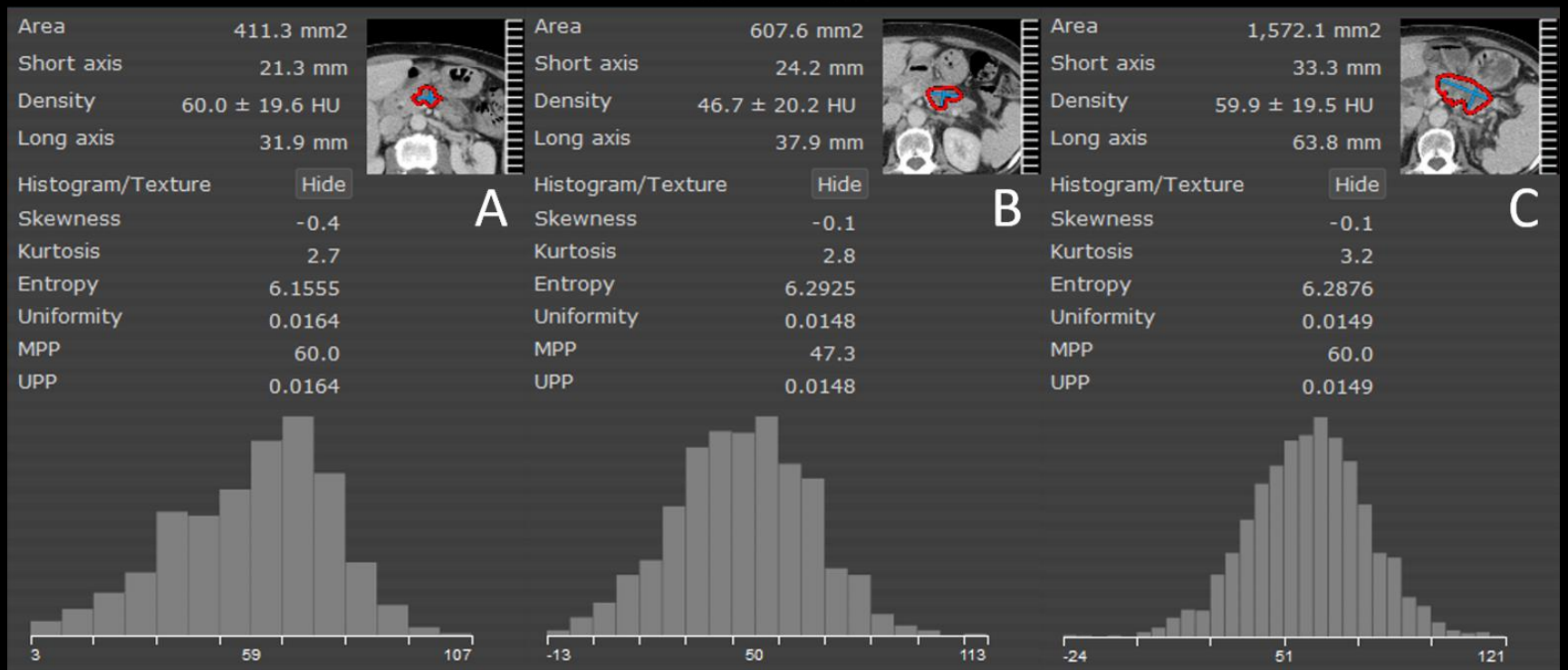

Per gentile concessione del Dott. Raimondi.

Conclusioni

Identificazione
- *CECT (+ MR/MRCP/DWI + EUS)*

Caratterizzazione
- *CECT + RM/EUS (+ biopsia)*

Tumor staging
- *CE-CT*
- *CE-MR ed EUS complementary*
- *PET-CT in high risk patients*

Stratificazione del paziente e planning preoperatorio (valutazione multidisciplinare)

Valutazione risposta alla terapia neoadiuvante e follow-up