Non-contrast Enhanced MRI in Stroke

Meiyun Wang MD, PhD

Henan Provincial People's Hospital
Zhengzhou, China

Disclosure

I have no financial interests or relationships to disclose with regard to the subject matter of this presentation.

Henan Provincial People's Hospital

≈Henan General Hospital

- 1 hundred million people in Henan Province
- 6500 in-patient beds

- **Where is it?**


黑龙江
吉林
内蒙古自治区
新疆维吾尔自治区
甘
青海
河
山
北
渤海
辽宁
陕西
山东
黄海
江苏
安徽
西
西藏自治区
四
川
贵州
湖南
江西
福建
浙江
东海
云南
广东
台湾
赤尾屿
钓鱼岛
广西壮族自治区
香港
澳门
东沙群岛

- **How does it look like?**

Henan Provincial People's Hospital

The second in-patient building

The third in-patient building

One of the out-patient buildings

河南省人民医院
HENAN PROVINCIAL PEOPLE'S HOSP
20

The Research and Training building

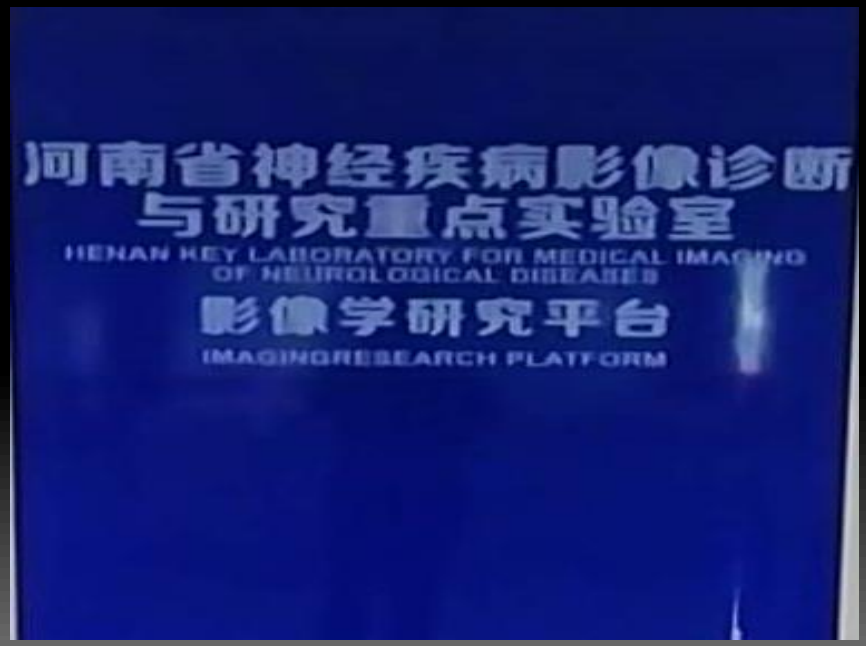

Henan Medical Imaging Center

Henan Medical Imaging Center

Henan Medical Imaging Center

- 240 staff
- 14 MR scanners:
  3.0T×10 (Prisma, Skyra, Trio, Verio, MR750…)
  1.5T×4 (Sempra, 360, HDe)
- 16 CTs
- 1 PET-MR, 1 PET-CT
- Intra-operative CT-MR-DSA system
- MR-guided Focused Ultrasound (Neuro+Body)
- 20 DSA……

Henan Medical Imaging Center

- **Average workload / Day**
  - –700 MRI cases
  - –1300 CT cases
  - –20--30 PET-CT cases
  - –1500 X Ray cases
  - –130 DSA cases

- **Collaborations: Clinical trials, big data, artificial intelligence(AI)…**

Non-contrast Enhanced MRI in Stroke

Advancement of MR in Neuroimaging

- **Conventional MRI**
  - T2w, T1w, FLAIR, DWI: Structural information
- **Advanced MRI**
  - **Functional MRI**
    - DTI / DKI, Perfusion, BOLD, MRS, SWI…
  - **Molecular MRI**
    - Exogenous contrast agents
    - **Endogenous contrast agents (protein, glucose) : No contrast agent, no delivery issue, no toxicity**

Today's Agenda

- Strategically Acquired Gradient Echo (STAGE)
- A Length and Offset Varied Saturation (LOVARS)

Today's Agenda

- **Strategically Acquired Gradient Echo (STAGE)**
- **A Length and Offset Varied Saturation (LOVARS)**

Susceptibility weighted imaging (SWI)

- **SWI** demonstrates a unique contrast caused by the difference of tissue susceptibility
- SWI is extremely sensitive in detecting intracranial hemorrhage and microbleeds
- SWI can be used to measure oxygen saturation and iron content

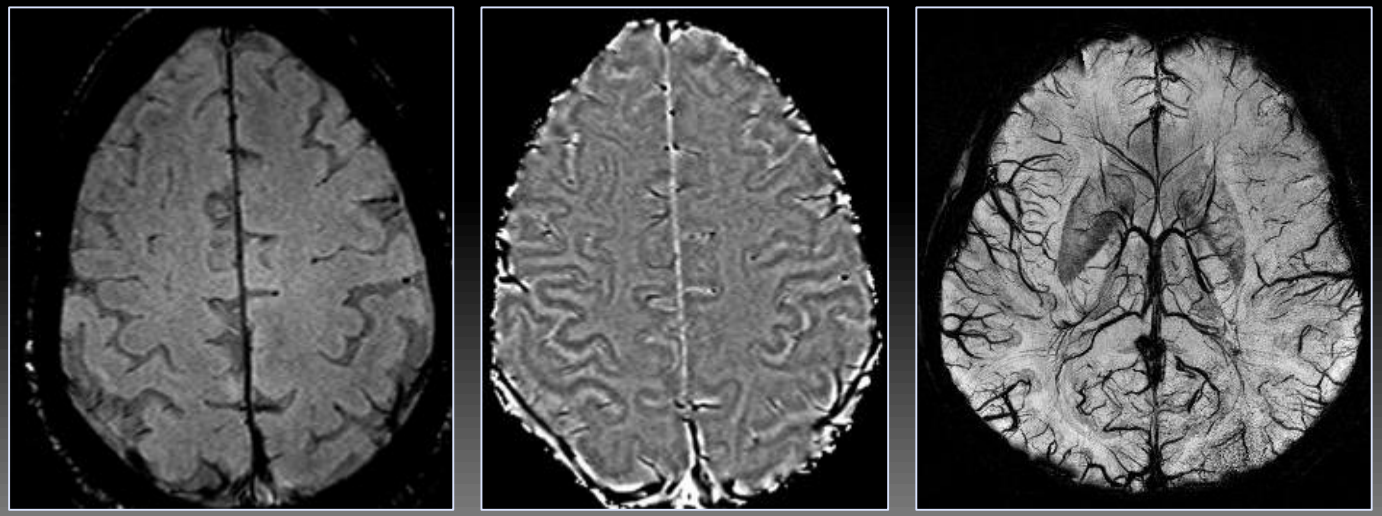

SWI: Early detecting hemorrhage within ischemia

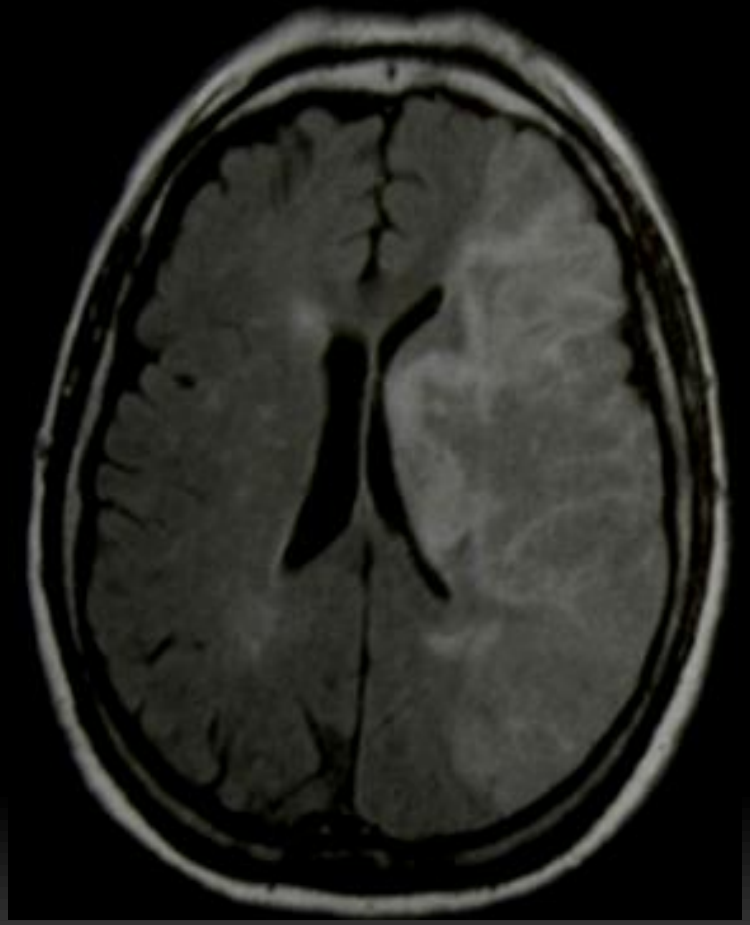

FLAIR

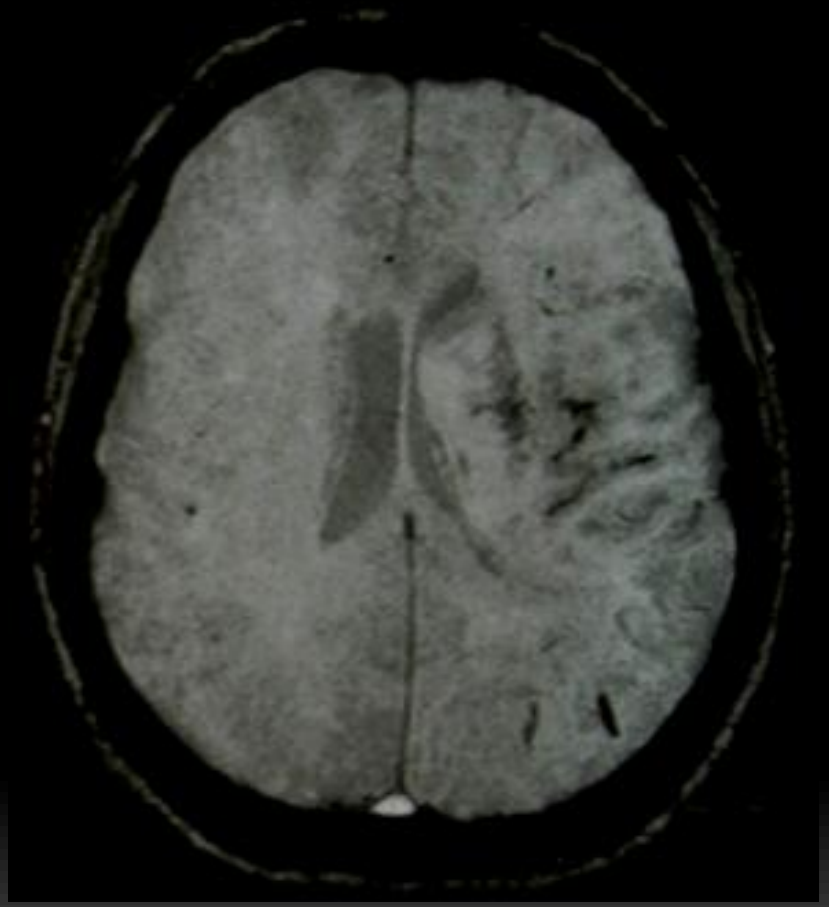

SWI

SWI: Demonstrating areas of hypo-perfusion

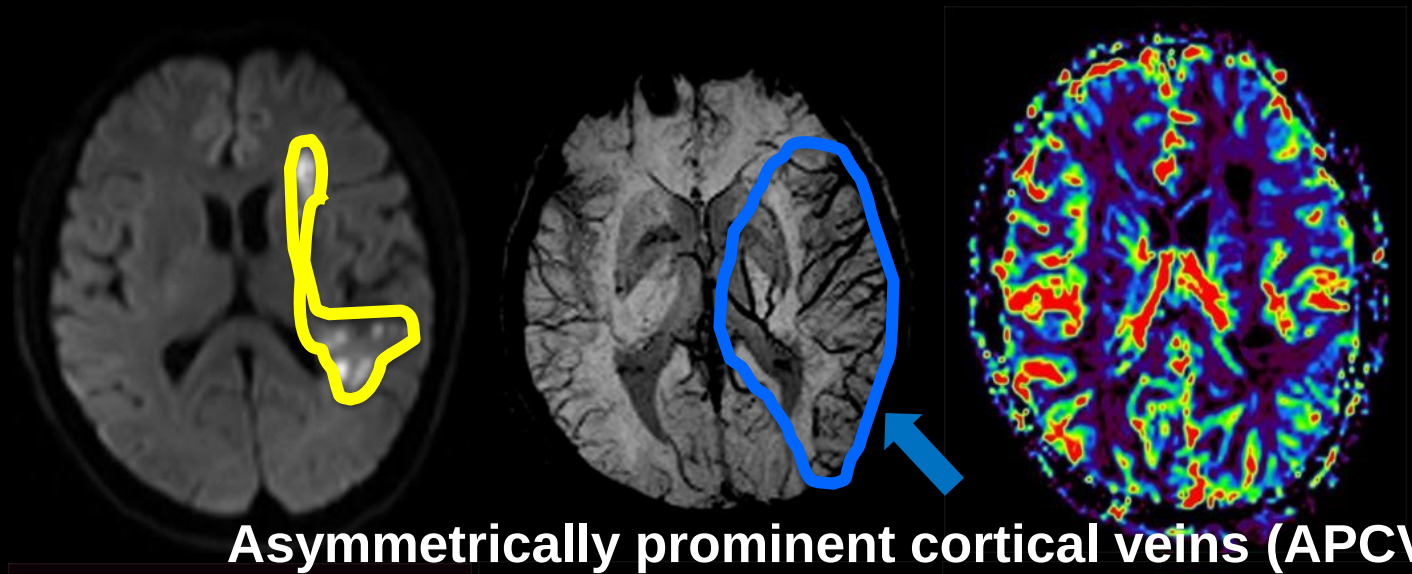

Asymmetrically prominent cortical veins (APCV)

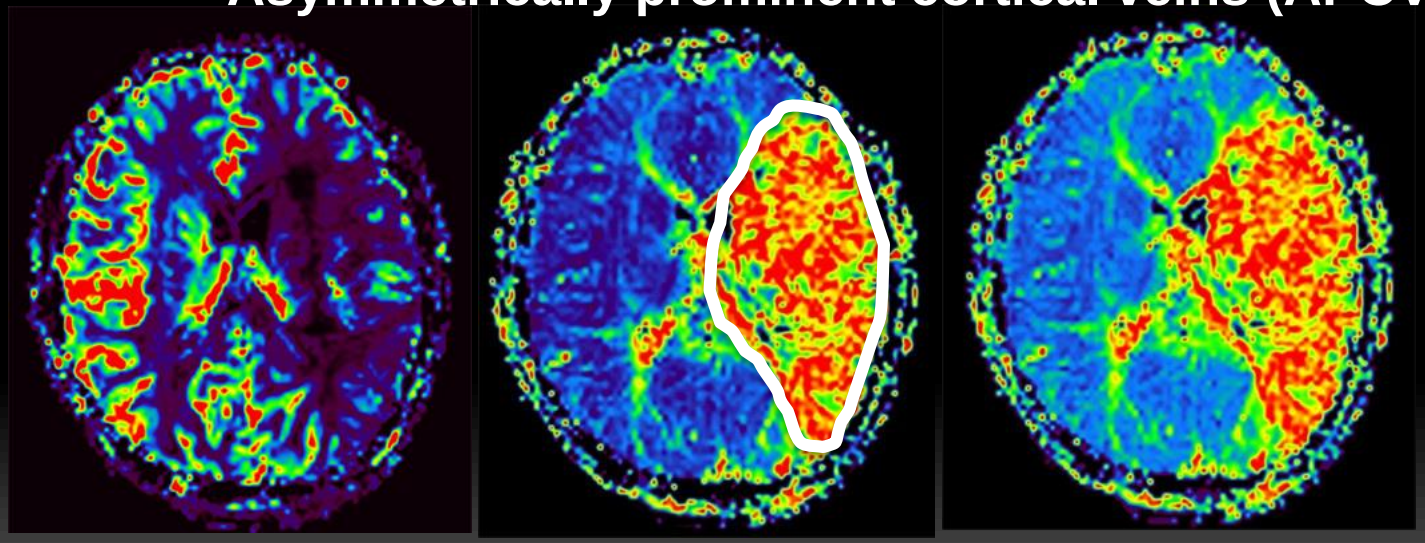

SWI / DWI mismatch: Ischemic penumbra

SWI mapping (SWIM): Predicting early prognosis

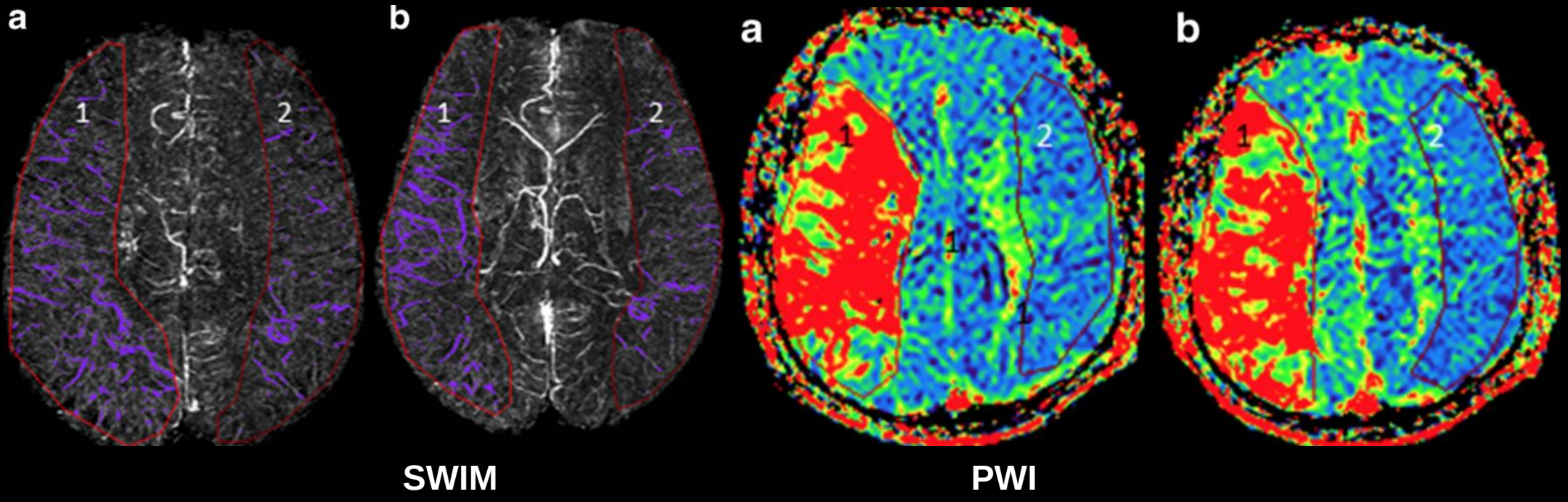

Patients with Asymmetrically prominent cortical veins (APCV) tend to have worse outcomes

Meiyun Wang, et al. European Radiology, 2016

European Radiology, 2016



Eur Radiol
DOI 10.1007/s00330-016-4593-y

MAGNETIC RESONANCE

Increased susceptibility of asymmetrically prominent cortical veins correlates with misery perfusion in patients with occlusion of the middle cerebral artery

Yu Luo[1] · Zhongying Gong[2] · Yongming Zhou[1] · Binge Chang[3] · Chao Chai[4] · Taiyuan Liu[5] · Yanhong Han[5] · Meiyun Wang[5] · Tianyi Qian[6] · E Mark Haacke[7] · Shuang Xia[4]

Strategically Acquired Gradient Echo (STAGE)

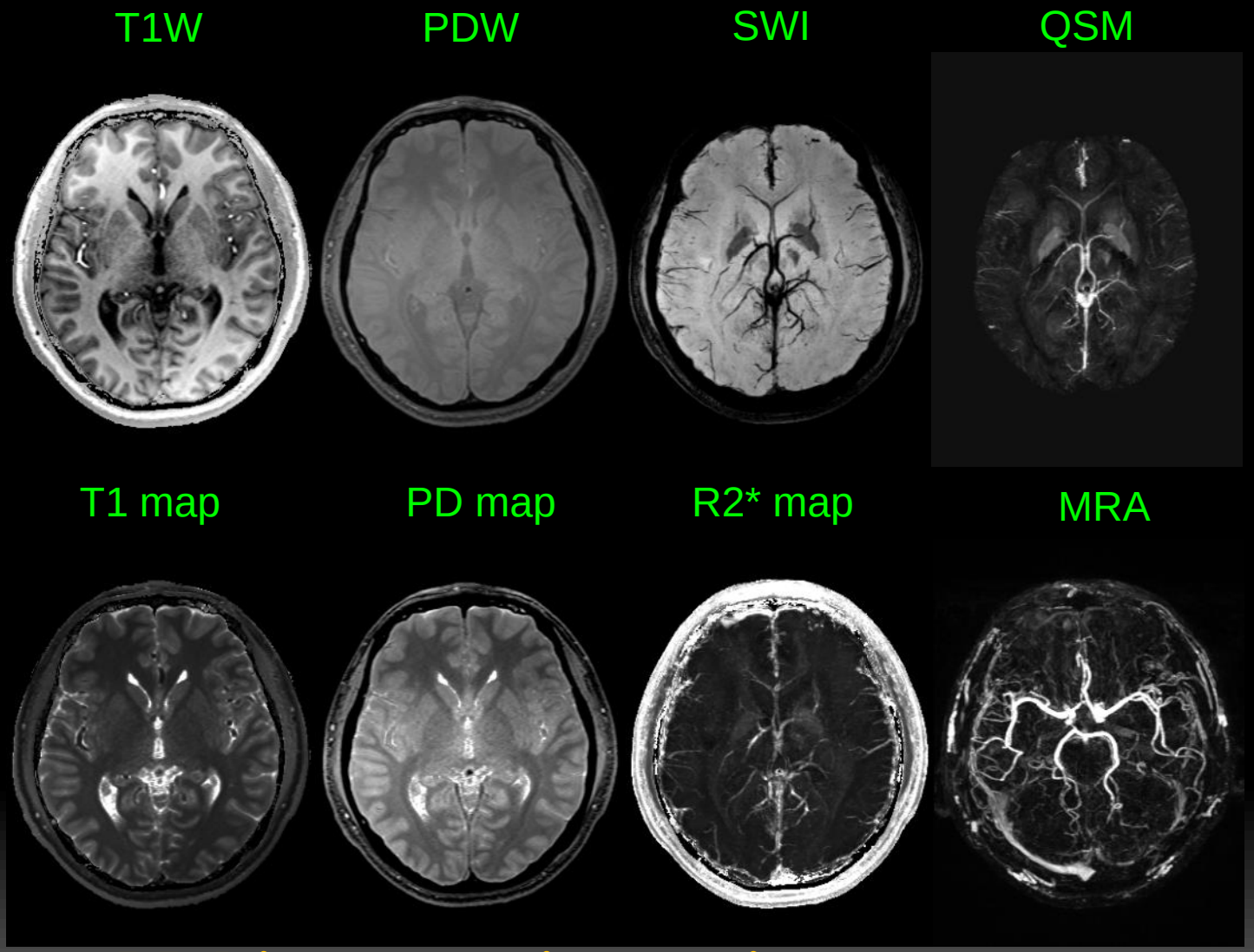

Multi-contrast images in one scan

c/o Dr. E. Mark Haacke

STAGE

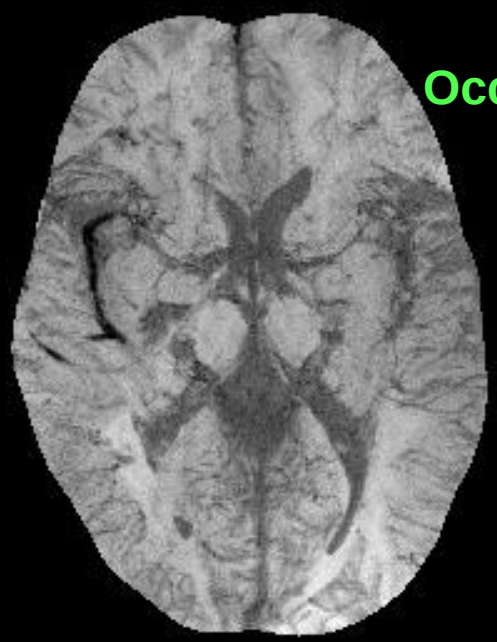

Occlusion

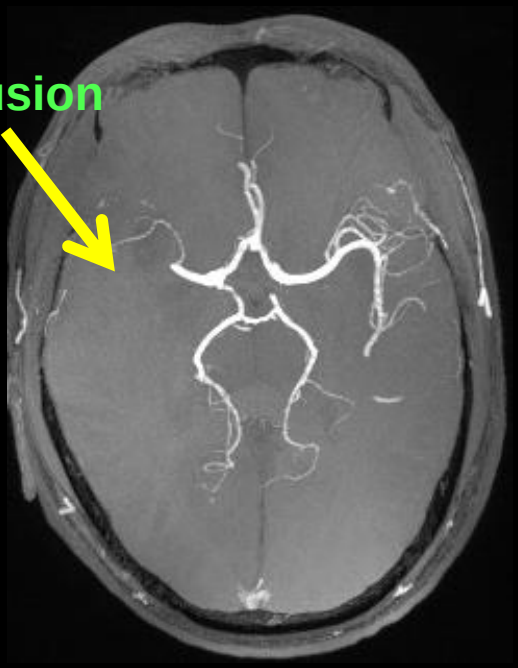

APCV sign

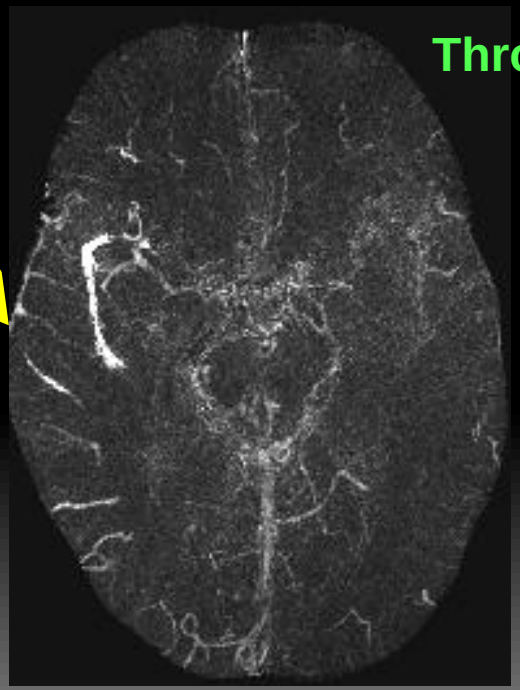

Thrombus

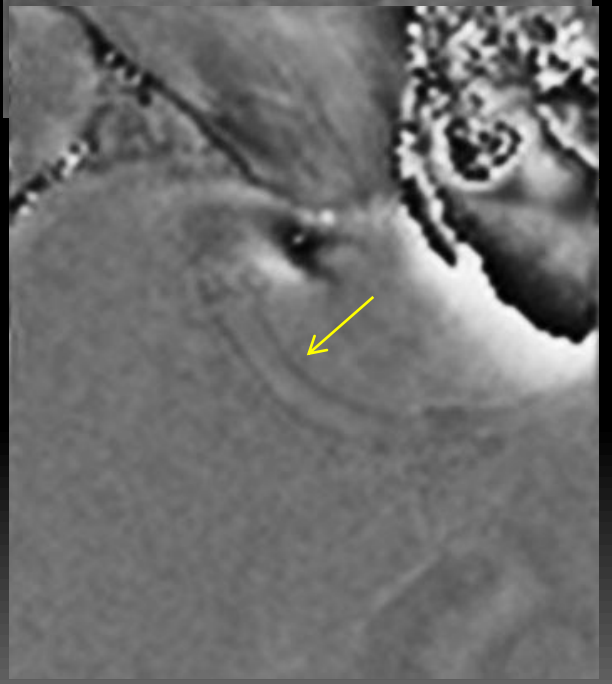

Today's Agenda

- Strategically Acquired Gradient Echo (STAGE)
- **A Length and Offset Varied Saturation (LOVARS)**

Advancement of CEST

- **Chemical Exchange- dependent Saturation Transfer (CEST):**

  A molecular MRI method to detect low-concentration chemicals indirectly using the water signal

Ward & Balaban, JMRI 2000

Advancement of CEST

- **paraCEST (paramagnetic CEST, Zhang & Sherry, JACS 2001; Aime et al. MRM 2002)**
- **gagCEST (glycosaminoglycans, Ling et al. PNAS 2008)**
- **GluCEST (glutamates, Cai et al. Nat. Med. 2012)**
- **GlucoCEST (glucoses, Chan et al. MRM 2012; Walker-Samuel et al. Nat. Med. 2013)**

Advancement of CEST

- **Amide Proton Transfer (APT) : Detecting endogenous mobile proteins and peptides in tissue** (Zhou et al. Nat. Med. 2003)
- **Length and Offset Varied Saturation (LOVARS) : Detecting endogenous macromolecules and metabolites in tissue**

  (Song, et al. Nat. Comm. 2015)

APT / LOVARS in Stroke

- **Early detection** of cerebral ischemia
- **Early separation** of cerebral ischemia and intracranial hemorrhage (ICH)

MRI of acute ischemia: predict infarction

Sun et al. JCBFM, 27(2007)1129

Male, 26 ys. Wake-up Stroke

DWI

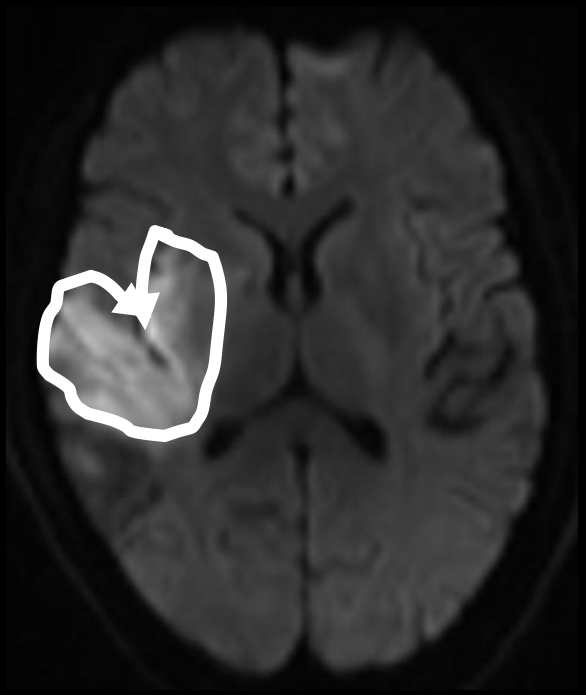

APT

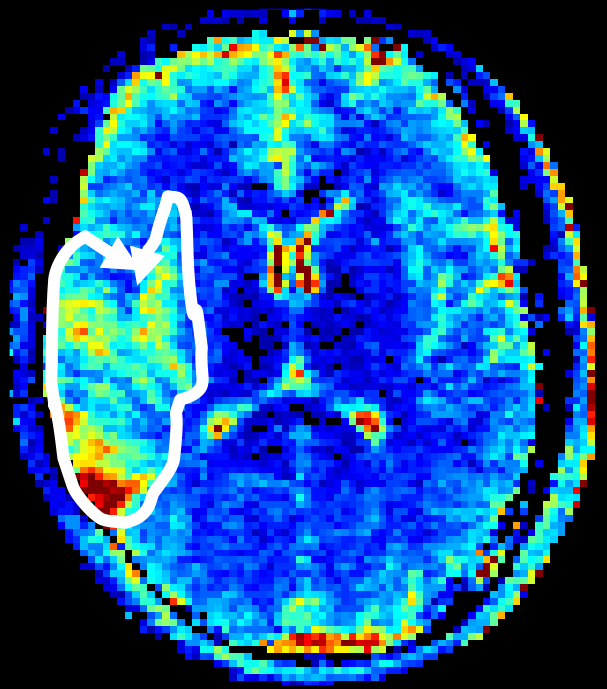

PWI

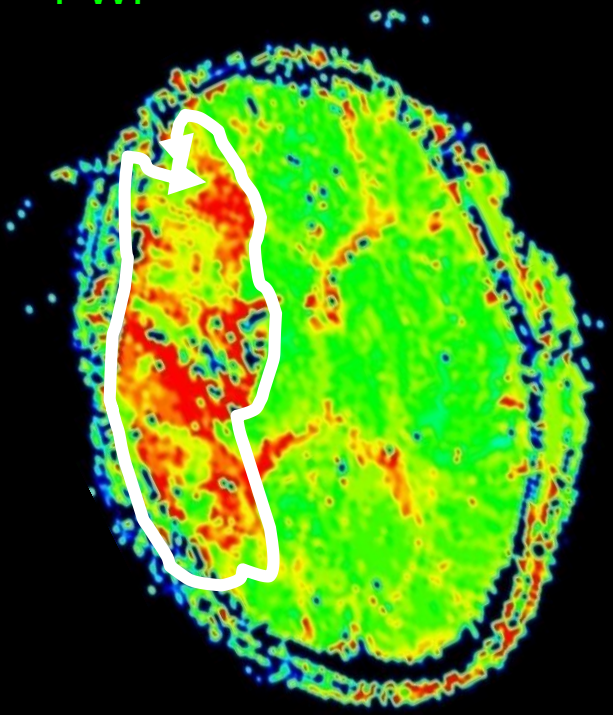

APT / DWI mismatch: Ischemic penumbra?

PWI / APT mismatch: Benign oligemia ?

Diagnostic process for stroke

- **CT:** Excluding intracranial hemorrhage
- **Further MRI:** Early detection and evaluation of cerebral ischemia

Time is brain

Hyperacute ICH and cerebral ischemia

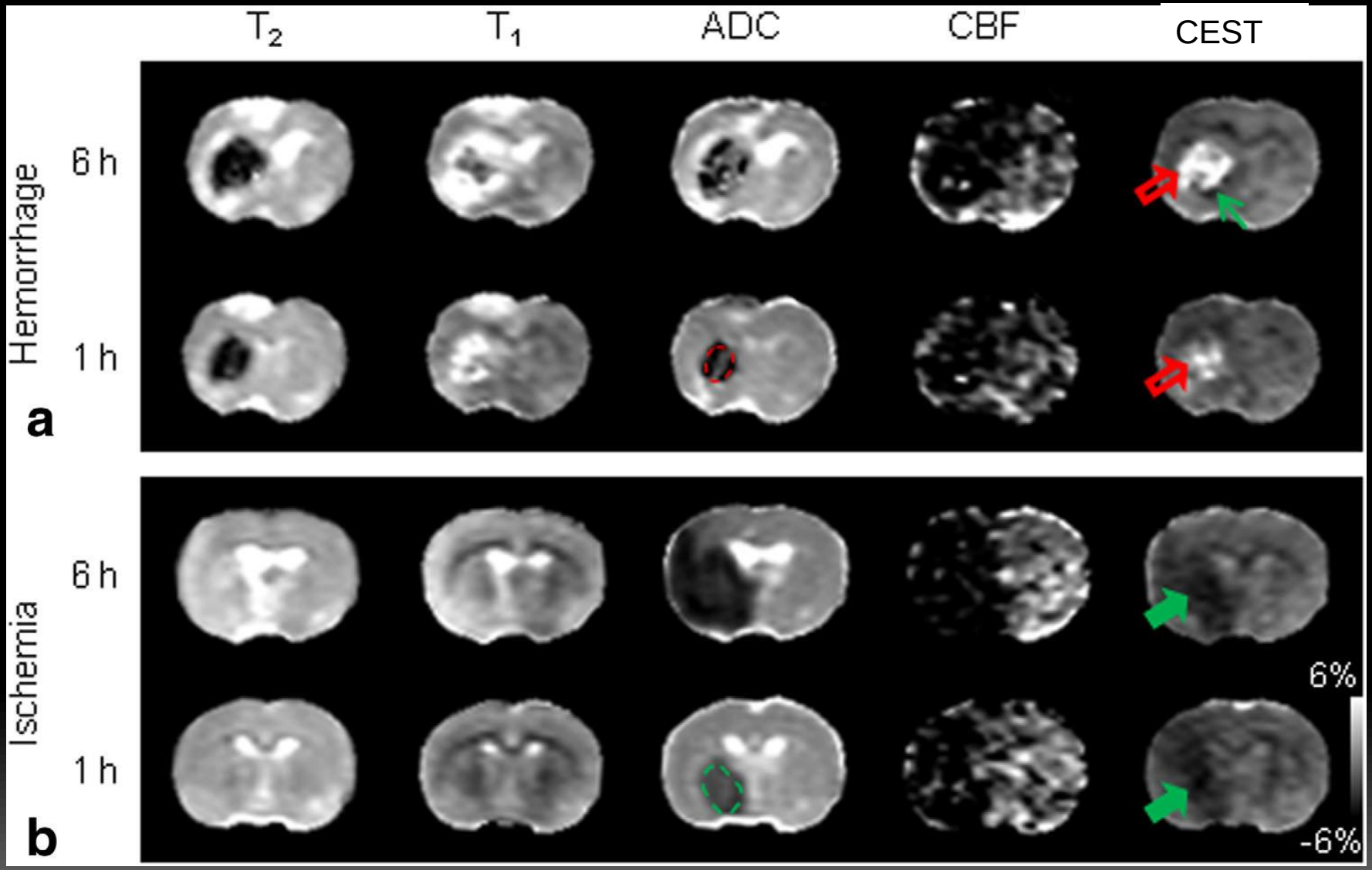

Meiyun Wang, et al. MRM, 2015

Meiyun Wang, Jinyuan Zhou, et al.
Simultaneous detection and separation of hyperacute intracerebral hemorrhage and cerebral ischemia using amide proton transfer MRI. Magn Reson Med. 2015

RAPID COMMUNICATION

Magnetic Resonance in Medicine 00:00–00 (2015)

Simultaneous Detection and Separation of Hyperacute Intracerebral Hemorrhage and Cerebral Ischemia Using Amide Proton Transfer MRI

Meiyun Wang,[1†] Xiaohua Hong,[1†] Che-Feng Chang,[2†] Qiang Li,[2†] Bo Ma,[1] Hong Zhang,[1] Sinan Xiang,[1] Hye-Young Heo,[1] Yi Zhang,[1] Dong-Hoon Lee,[1] Shanshan Jiang,[1] Richard Leigh,[3] Raymond C. Koehler,[2] Peter C. M. van Zijl,[1,4] Jian Wang,[2*] and Jinyuan Zhou[1,4*]

APT in Hyperacute ICH and cerebral ischemia

Ischemia

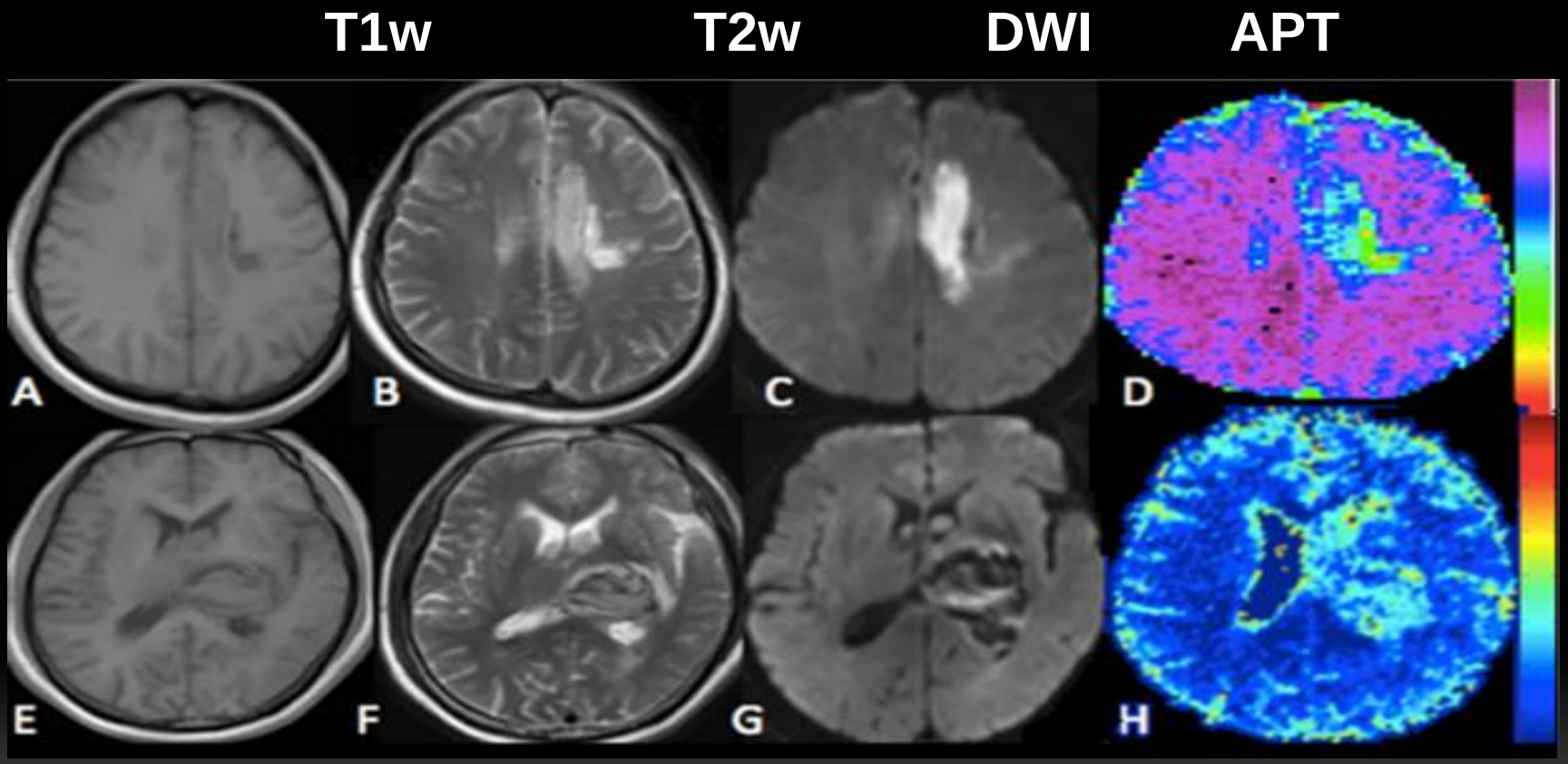

Hemorrhage

LOVARS

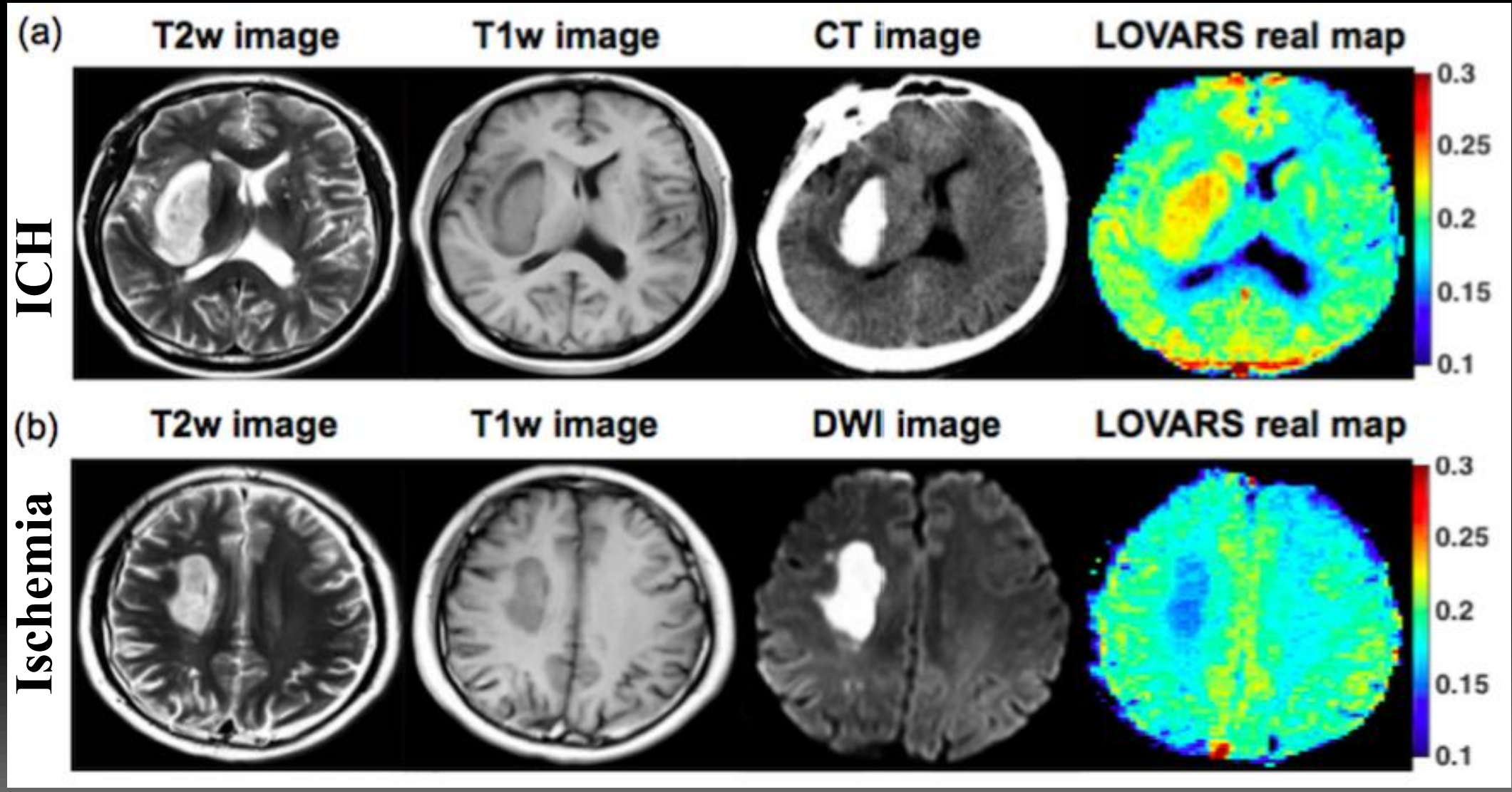
(a)
T2w image
T1w image
CT image
LOVARS real map
ICH
0.3
0.25
0.2
0.15
0.1
(b)
T2w image
T1w image
DWI image
LOVARS real map
Ischemia
0.3
0.25
0.2
0.15
0.1

Time is brain

Henan Aviation Rescue Base

Image is brain

Mobile Stroke Unit (MSU)

Future: One stop MRI ?

- With APT / LOVARS, one stop MRI may help to simplify the diagnostic process of stroke and improve the prognosis of stroke patients with lower cost

Summary

- **STAGE / APT / LOVARS are non-contrast enhanced MRI techniques**
  - **Detection of hemorrhage within ischemia**
  - **Evaluation of Penumbra**
  - **Early detection and separation of ischemia and intracranial hemorrhage…**

Acknowledgement

- Henan Provincial People's Hospital
  - Yan Bai
  - Xiaoyue ma
  - Wei wei
  - Jing Zhou
  - Taiyuan Liu
- Wayne State University
  - E. Mark Haacke
- Johns Hopkins Hospital
  - Jinyuan Zhou
  - Xiaolei Song

Thanks for your attention!

Contact information:
Meiyun Wang
mywang@ha.edu.cn
Wechat: 138-3710-1920