Società Medico Chirurgica di Ferrara dal 1846



Con il Patrocinio

Ordine dei Medici Chirurghi e degli Odontoiatri della provincia di FERRARA

AME

sie Società Italiana Endocrinologia

Obesità: oltre il peso
Stili di vita e terapie innovative

Sabato 31 ottobre 2026

Aula Magna Nuovo Arcispedale S. Anna

Cona, Ferrara

Obesità ipotalamiche

Pietro Maffei

Clinica Medica 3

Dipartimento di Medicina (DIMED)

Università degli Studi di Padova

pietro.maffei@unipd.it

UNIVERSA UNIVERSIS PATAVINA LIBERTAS 1222

Endo-ERN
European Reference Network on Rare Endocrine Conditions

AZIENDA OSPEDALE UNIVERSITÀ PADOVA

Prime osservazioni cliniche di colleghi neurologi…

Parigi e Vienna 1900…



Joseph Babinski

(1857-1932)

Séance du jeudi 7 juin 1900.

PRÉSIDENCE DE M. LE PROFESSEUR JOFFROY

VI. — **Tumeur du Corps Pituitaire sans Acromégalie et avec Arrêt de Développement des Organes Génitaux**, par M. J. BABINSKI.

L'observation anatomo-clinique que je rapporte succinctement est incomplète et, par conséquent, susceptible d'être critiquée; elle me paraît digne toutefois d'être relatée, malgré ses imperfections.

Il s'agit d'une jeune fille de 17 ans que j'ai observée il y a dix ans. Elle se plaignait de douleurs de tête qui avaient apparu environ trois ans auparavant, avaient augmenté d'intensité petit à petit et étaient devenues très violentes. Depuis plusieurs mois elle était sujette à des crises épileptiformes, et sa vue s'était notablement affaiblie.

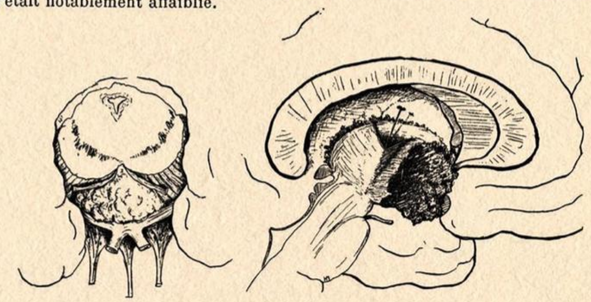

La nécropsie décela l'existence d'une tumeur qui occupait la selle turcique, adhérait au corps pituitaire et englobait le tuber cinereum (voir fig. 3 et 4, exécutées d'après des dessins de mon ami M. Meige). Ce néoplasme a été examiné histologiquement par M. Onanoff, qui a fait de cette étude l'objet de sa thèse (1). Il s'agit, d'après M. Onanoff, d'un épithélioma développé aux dépens de l'épithélium de la glande pituitaire, du type malpighien, en pleine évolution hyperplasique s'effectuant par division indirecte, avec dégénérescence myxomateuse du stroma conjonctif.

Les ovaires et l'utérus sont très petits; d'après leurs dimensions ils sembleraient appartenir à une fillette de 8 à 10 ans.

Cette observation est intéressante à deux points de vue : d'une part, l'absence d'acromégalie, de gigantisme contraste avec l'existence d'une grosse tumeur du corps pituitaire; mais, à la vérité, pour que ce fait fût très instructif, il serait

(1) ONANOFF. *Sur un cas d'épithélioma.* Thèse de Paris, 1892.

Originalartikel, Berichte aus Kliniken und Spitälern.

Aus der I. medicinischen Klinik des Herrn Hofrathes Prof. H. Nothnagel.

Ein Fall von Tumor der Hypophysis cerebri ohne Akromegalie.

Von **Dr. Alfred Fröhlich.***)

M. H.! Ich möchte mir erlauben, Ihnen einen Fall zu demonstrieren, den ich in dem von Herrn Professor v. Frankl-Hochwart geleiteten Nerven-Ambulatorium der Klinik des Herrn Hofrathes Nothnagel zu beobachten Gelegenheit hatte und der mir in mancherlei Hinsicht Bemerkenswertes darzubieten scheint.

R. D., ein 14jähriger Knabe, steht seit November 1899 in unserer Beobachtung. Damals gab seine Mutter an, dass er zweimal wöchentlich, zuweilen in 14tägigen Intervallen von der Schule mit Kopfschmerz nachhause kam. Er musste sich zu Bett legen; zwei Stunden nachher Erbrechen, mitunter Erbrechen gleich beim Nachhausekommen. Dieser Zustand bestand seit April 1899. Kopfschmerz links, zuweilen beiderseits, meist im Vorderkopf. Er lernt gut, gutes Gedächtnis, keine Zeichen von Nervosität oder Hysterie. Keine früheren Erkrankungen, kein vorangegangenes Trauma. Sehen gut. Sonst keinerlei subjective Beschwerden.

Keine Blasen- und Mastdarmstörungen. Objectiv konnte keinerlei pathologischer Befund festgestellt werden. In der Krankengeschichte erscheint der Status, des negativen Befundes ungeachtet, detaillirt erhoben. Fundus normal. Der Augenhintergrund ist, wie die Mutter mittheilt, zu jener Zeit auch von Professor Königstein untersucht und normal befunden worden. Wir nahmen angesichts des negativen Befundes einen Zustand von Hemicranie an und ertheilten dementsprechende therapeutische Rathschläge. Dann verloren wir Pat. aus den Augen.

*) Nach einer am 12. October 1901 in der Wanderversammlung des Vereines für Psychiatrie und Neurologie in Wien gehaltenen Demonstration.



Alfred Fröhlich

(1871-1953)

Primi modelli sperimentali…

Chicago 1940…

THE ANATOMICAL RECORD

Volume 78, 1940
Pages 149–172

HYPOTHALAMIC LESIONS AND ADIPOSITY IN THE RAT

A. W. Hetherington and S. W. Ranson
Institute of Neurology, Northwestern University Medical School, Chicago, Illinois

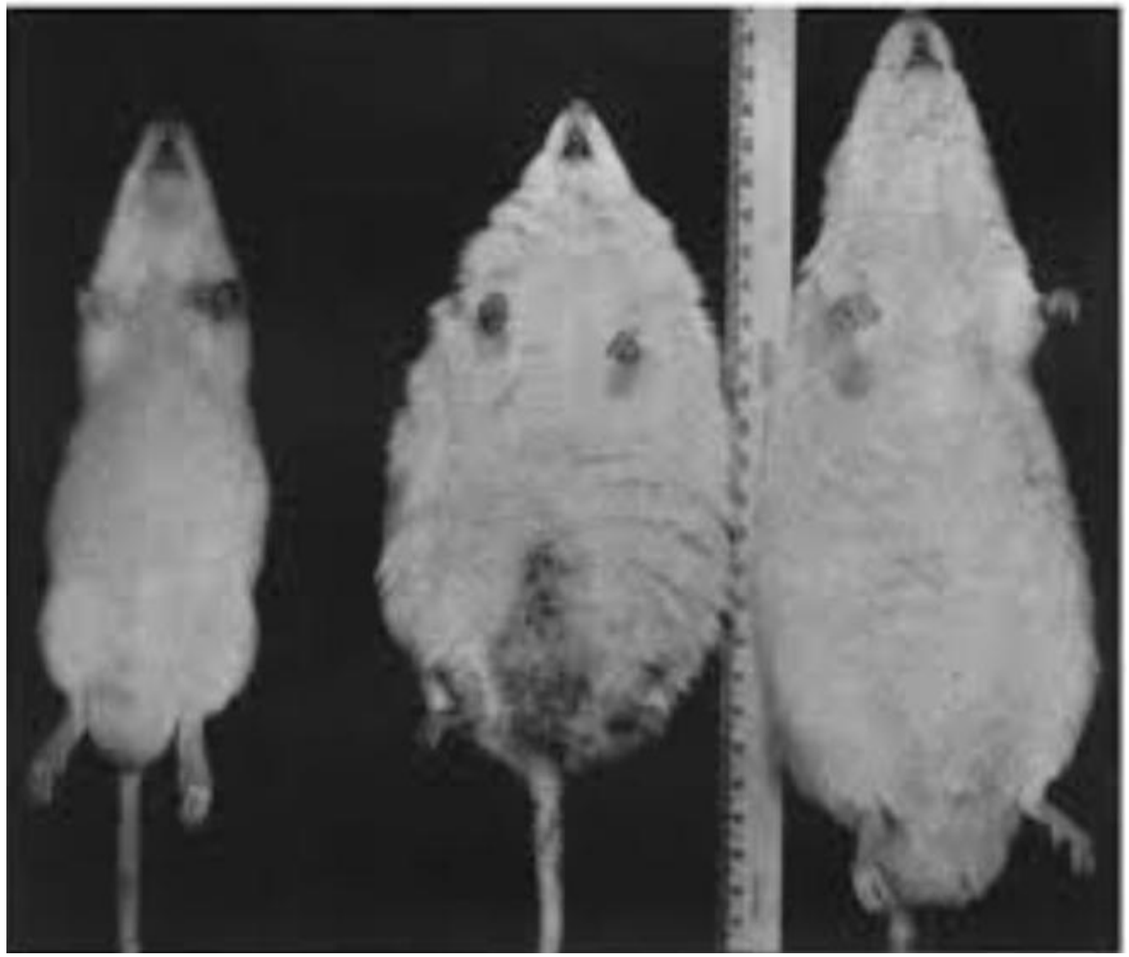

Ipotalamo e sistema limbico

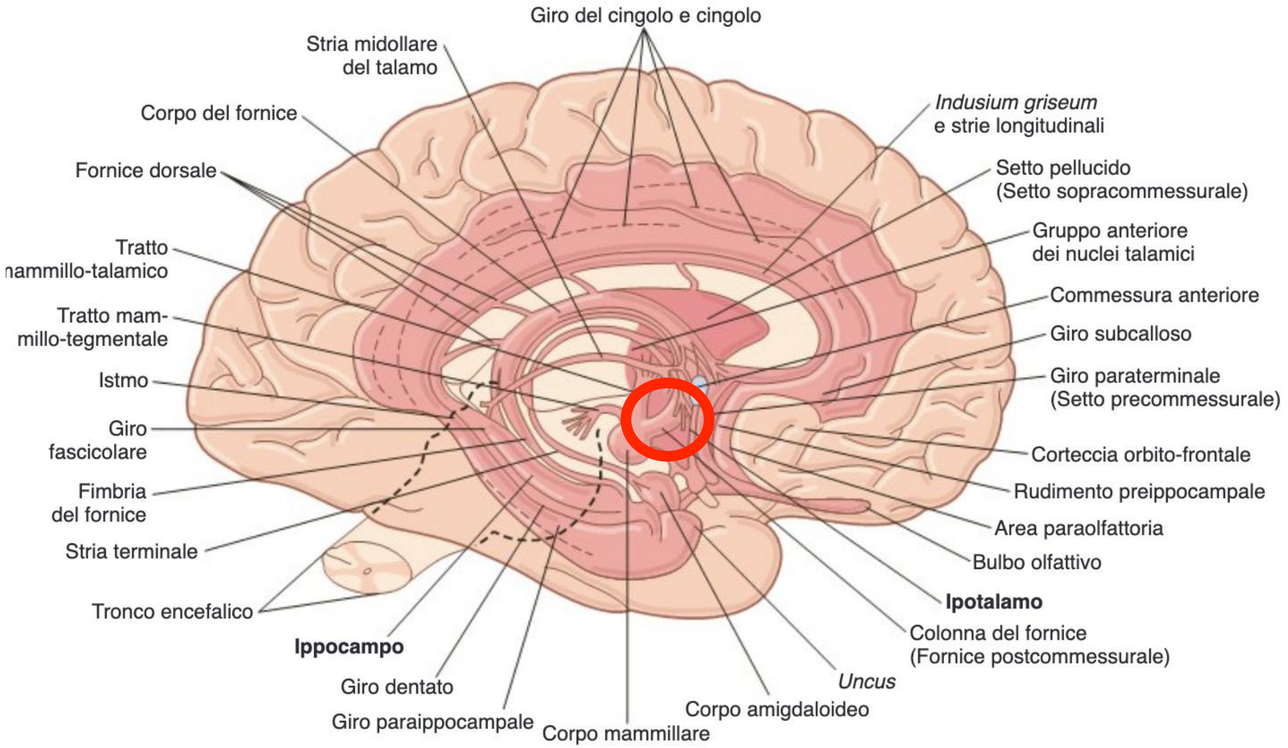

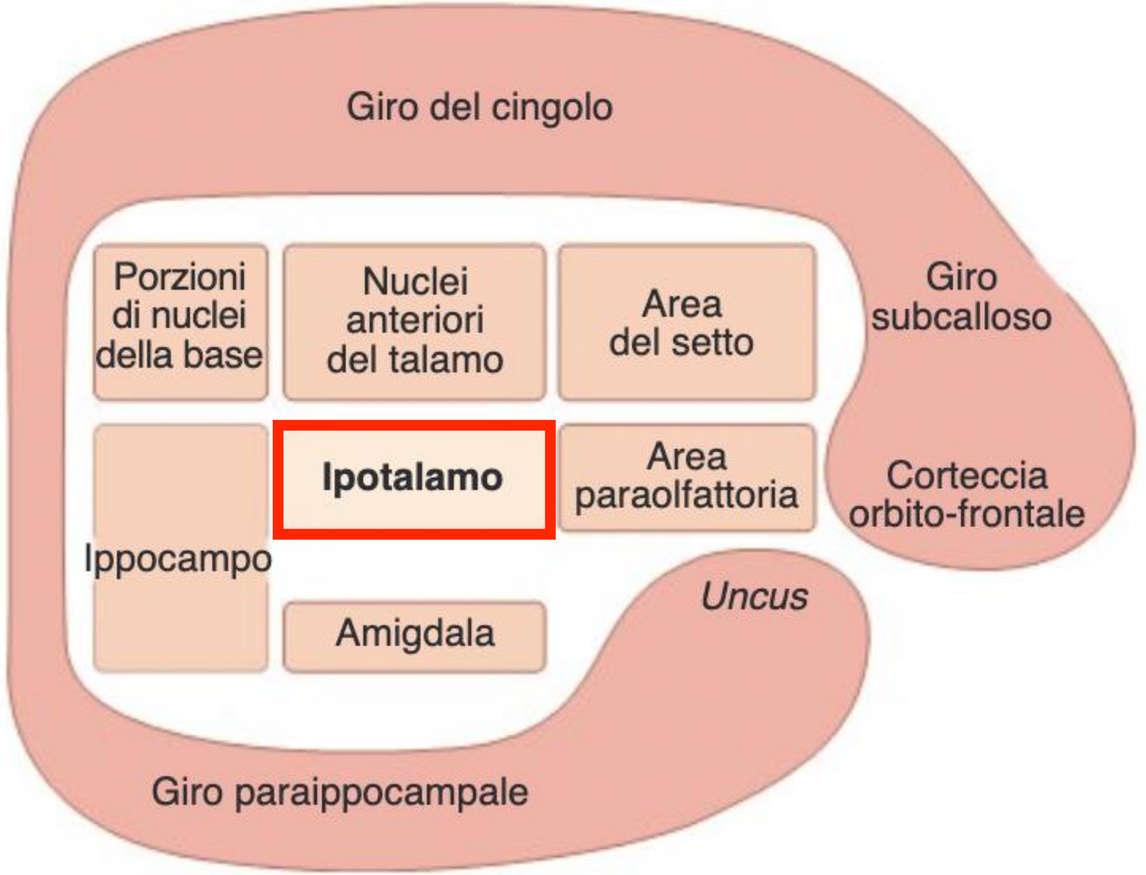

Circuiti neuroni che regolano le spinte motivazionali ed il comportamento emotivo dell'individuo e il mantenimento dell'omeostasi (temperatura, liquidi, peso…)

Guyton & Hall, Fisiologia Medica XIV edizione 2021

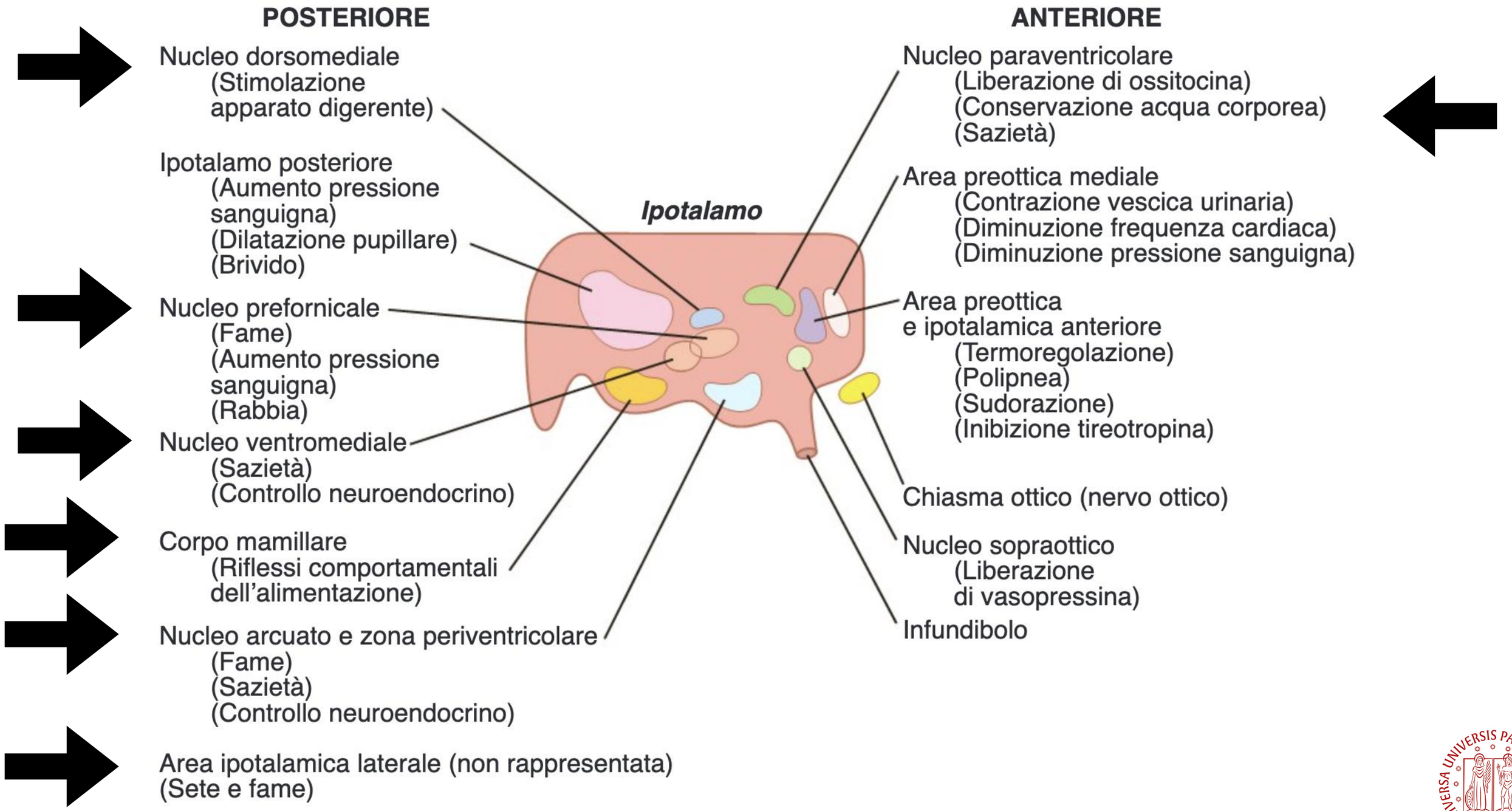

Guyton & Hall, Fisiologia Medica XIV edizione 2021

Obesity Originates in the Brain



Common Obesity

- **Nature:** Polygenic and multifactorial.
- **Drivers:** Complex interplay of genetic variants, lifestyle, and environment.
- **Prevalence:** Pandemic rates globally.

Hypothalamic Obesity (HO)

- **Nature:** Severe, early-onset, or acquired syndrome.
- **Drivers:** Individual pathogenic factors (genetic or acquired) destroying specific neural circuits.
- **Significance:** Provides the ultimate proof-of-concept for how brain circuits govern metabolic fate.

Modified from Argente et al, Lancet Diabetes Endocrinol 2025

Three Avenues of Hypothalamic System Failure

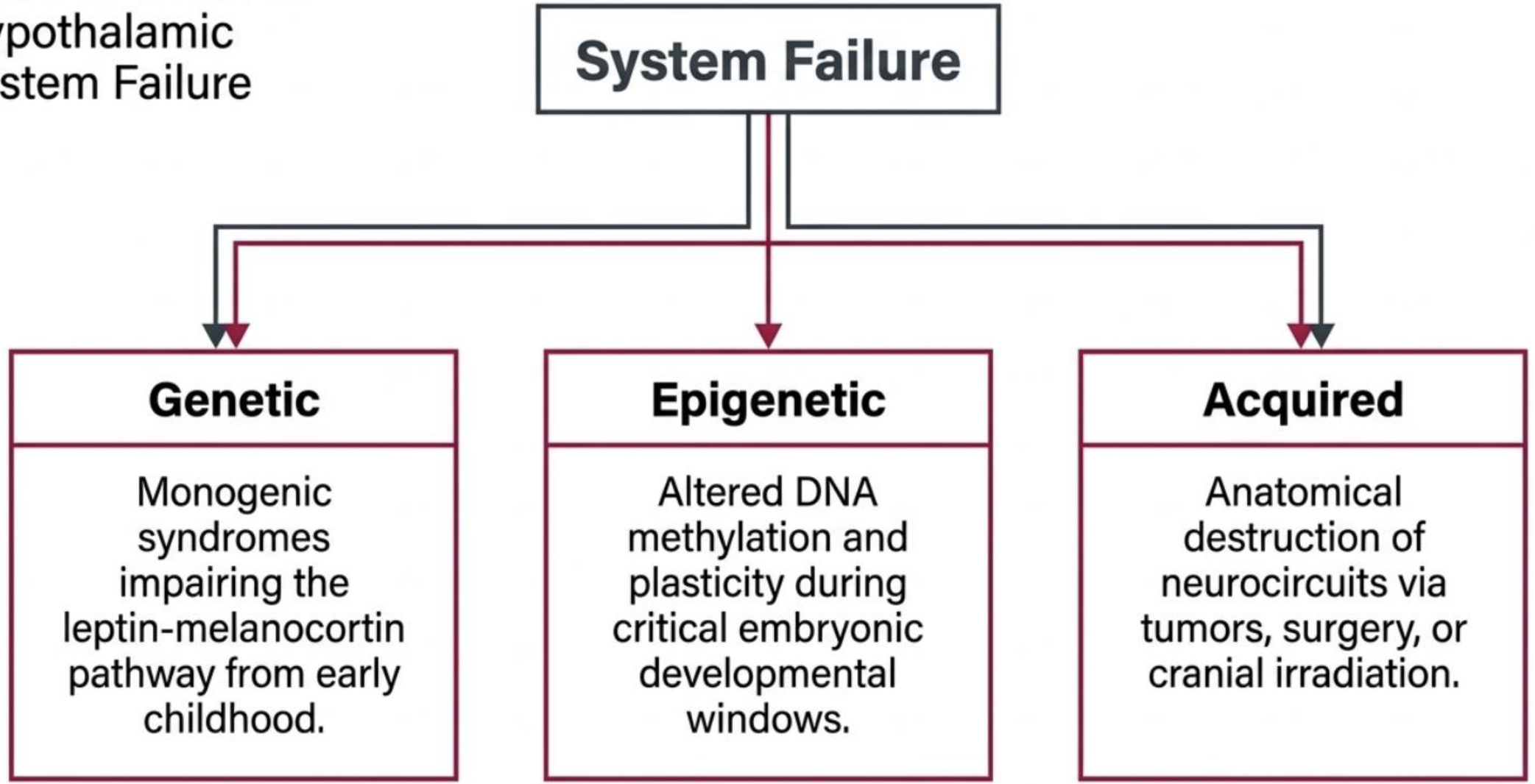

Modified from Argente et al, Lancet Diabetes Endocrinol 2025

Craniofaringioma

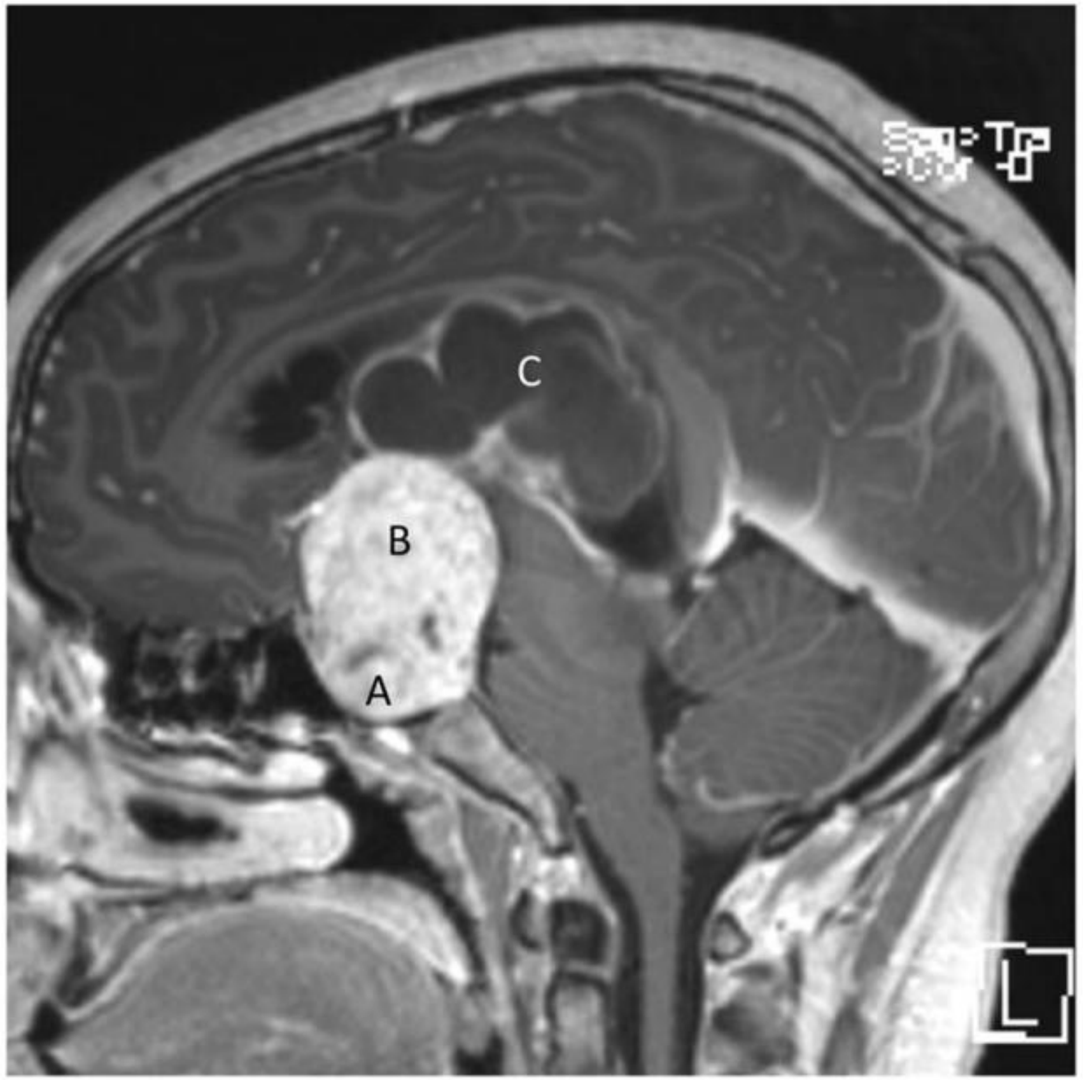

Drapeau et al, Child's Nervous System 2019

RMN normale

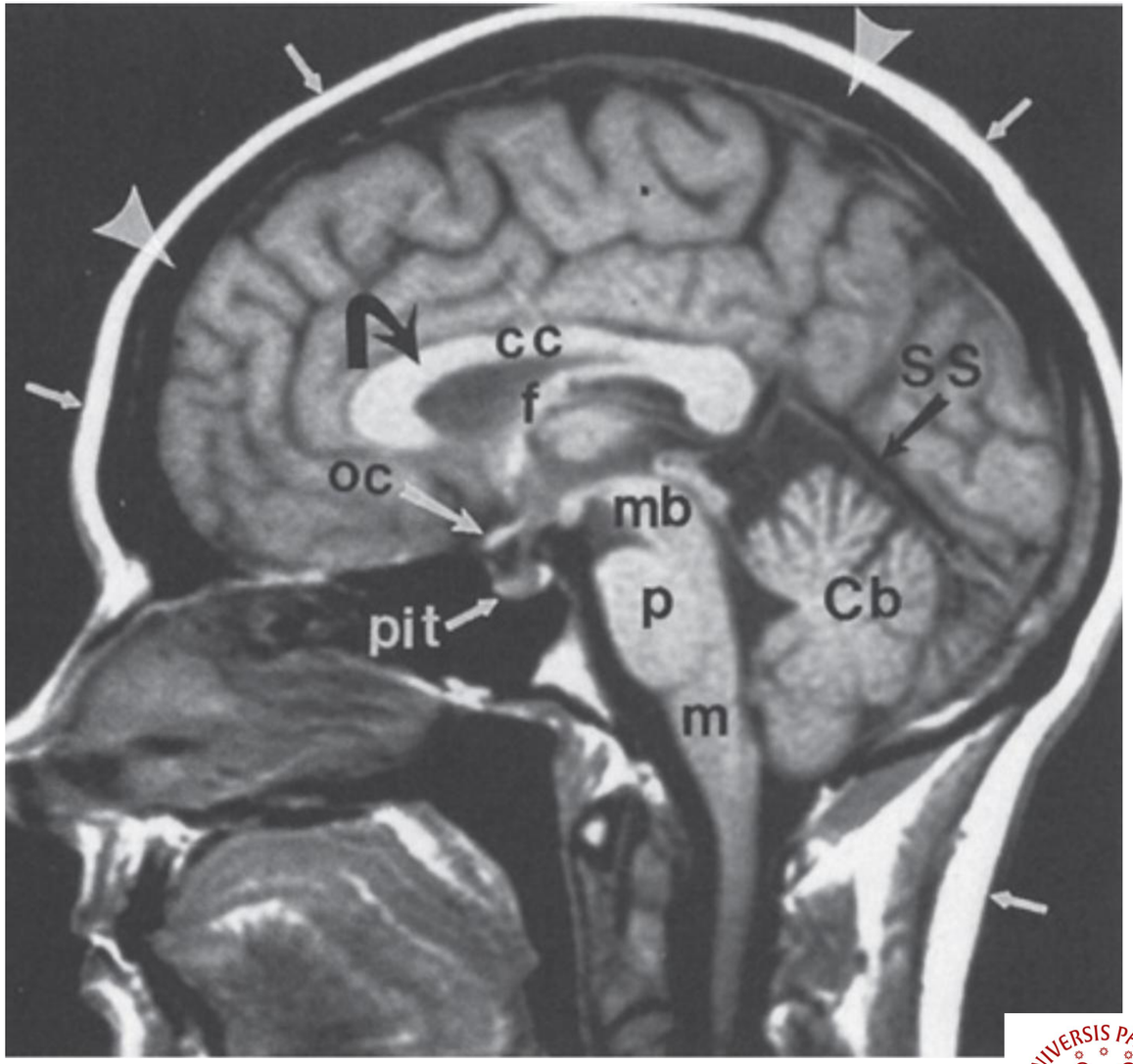

Chen et al, Basic Radiology, Mc-Graw-Hill 2011

The Double-Hit Pathology of Acquired Hypothalamic Obesity

The Primary Threat: Suprasellar Tumors.
Craniopharyngiomas account for up to 80% of childhood cases in this compartment.

Hit 1: Pre-Diagnosis

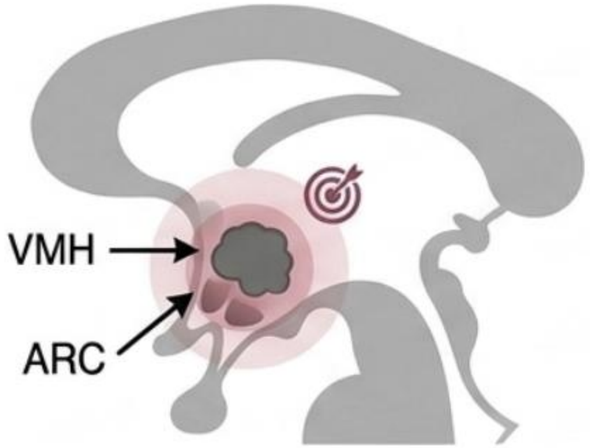

Excess weight gain begins before diagnosis as the growing tumor physically damages the VMH and ARC.

Hit 2: Post-Diagnosis Intervention



Despite high oncological cure rates (80-95%), aggressive surgical resection and cranial irradiation compound the initial anatomical destruction.

The Result: 77% of craniopharyngioma survivors develop severe, acquired hypothalamic obesity.

Modified from Argente et al, Lancet Diabetes Endocrinol 2025

Hypothalamic Obesity

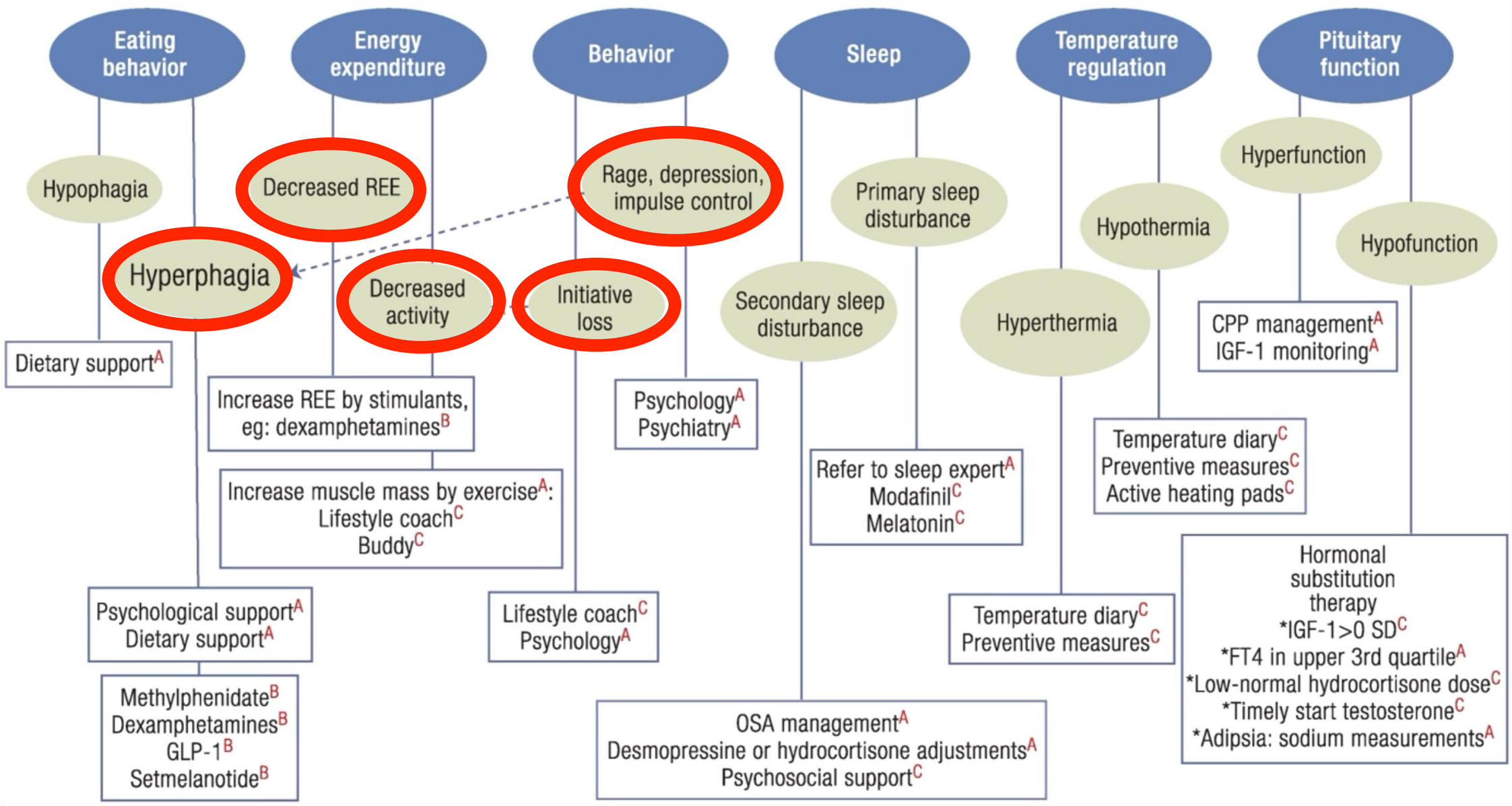

HL Muller et al, Frontiers in Endocrinology 2026

Microcircuitry of the central melanocortin system

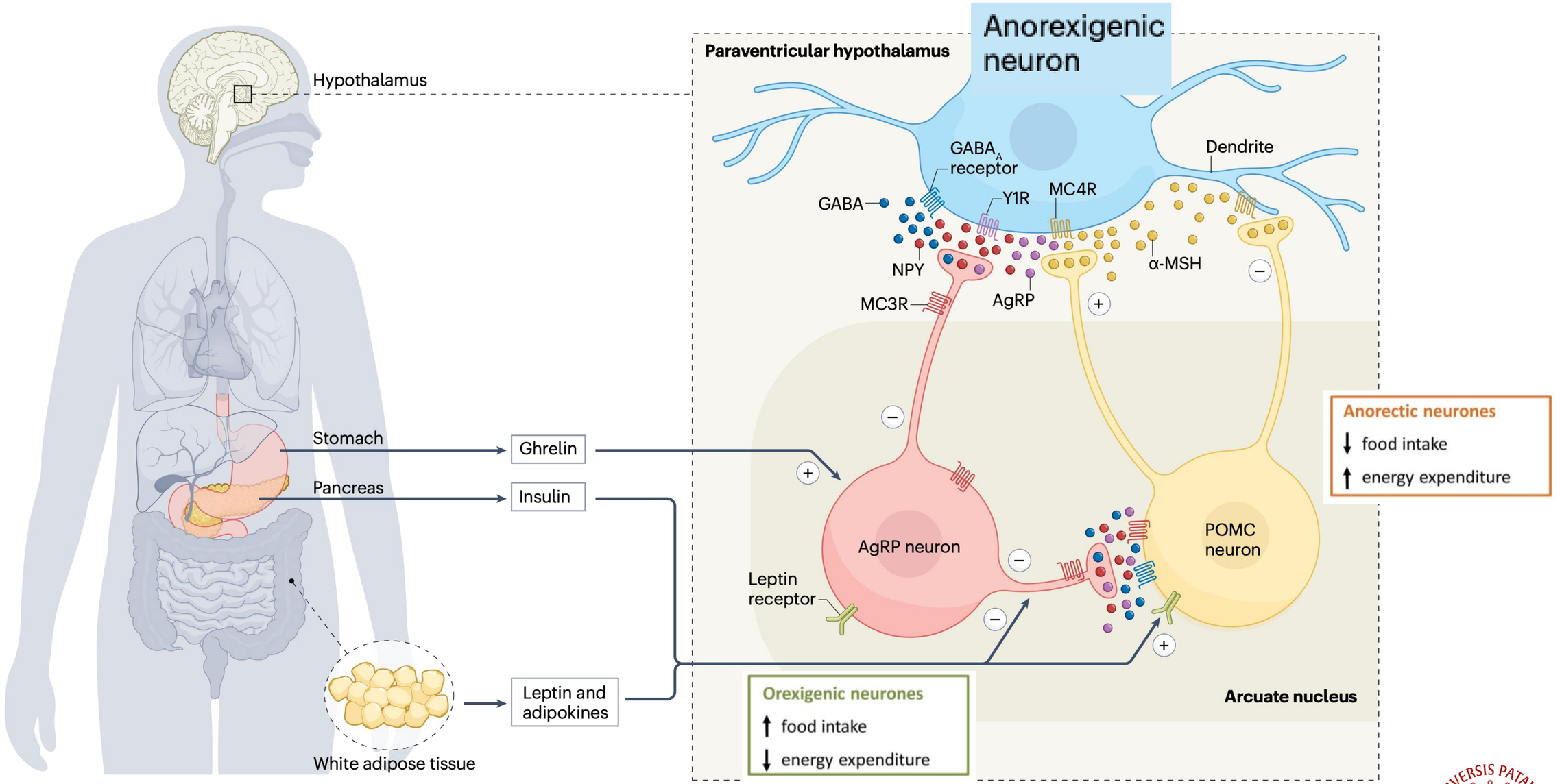

Sweeney et al, Nature Reviews Endocrinology 2023

Monogenic obesity syndromes involving the melanocortin system

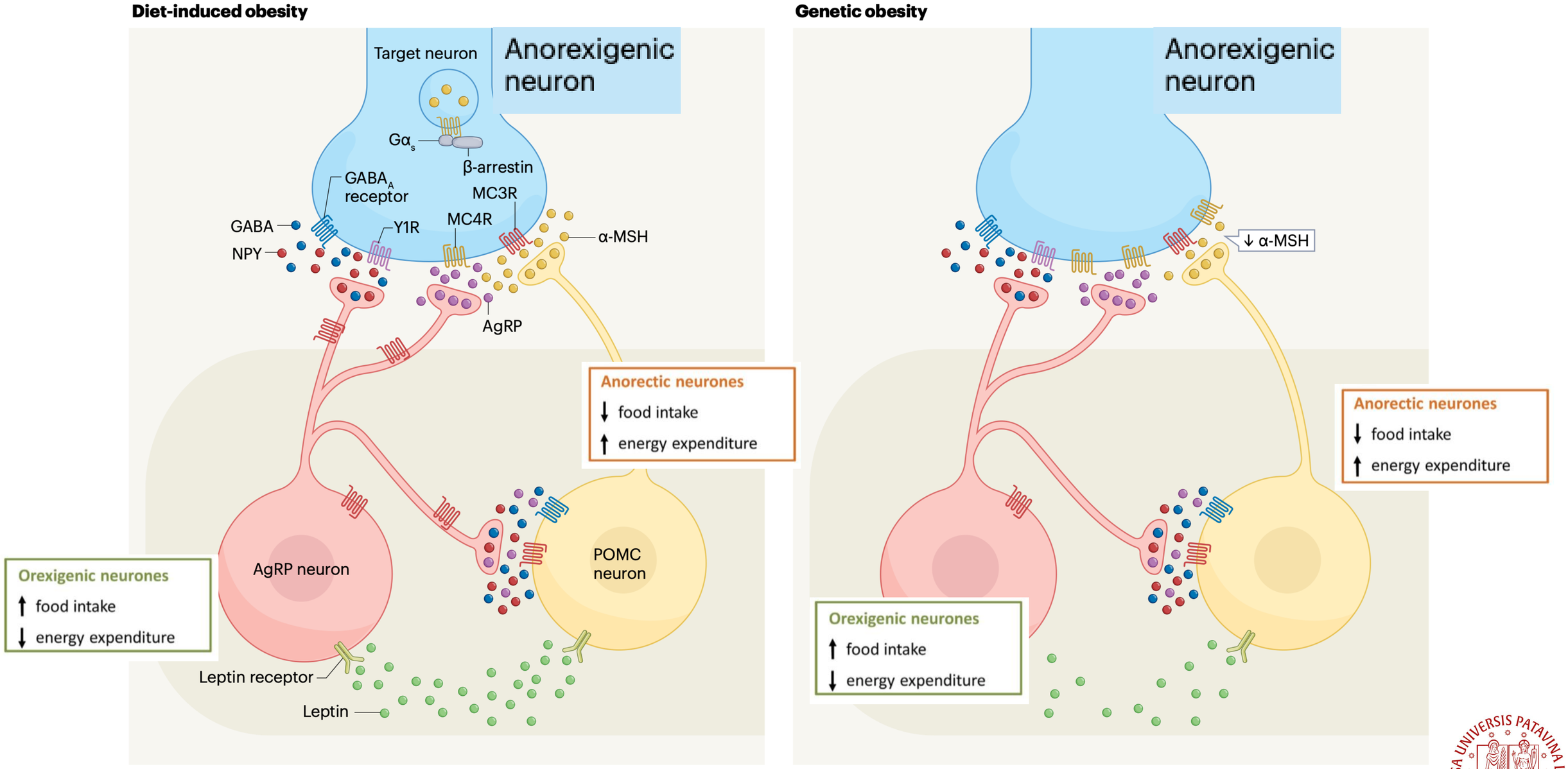

Sweeney et al, Nature Reviews Endocrinology 2023

Béatrice Dubern[a,b], Héléna Mosbah[c], Marie Pigeyre[d,e], Karine Clément[b,c], Christine Poitou[b,c,*]

Annales d'Endocrinologie 83 (2022) 63–72

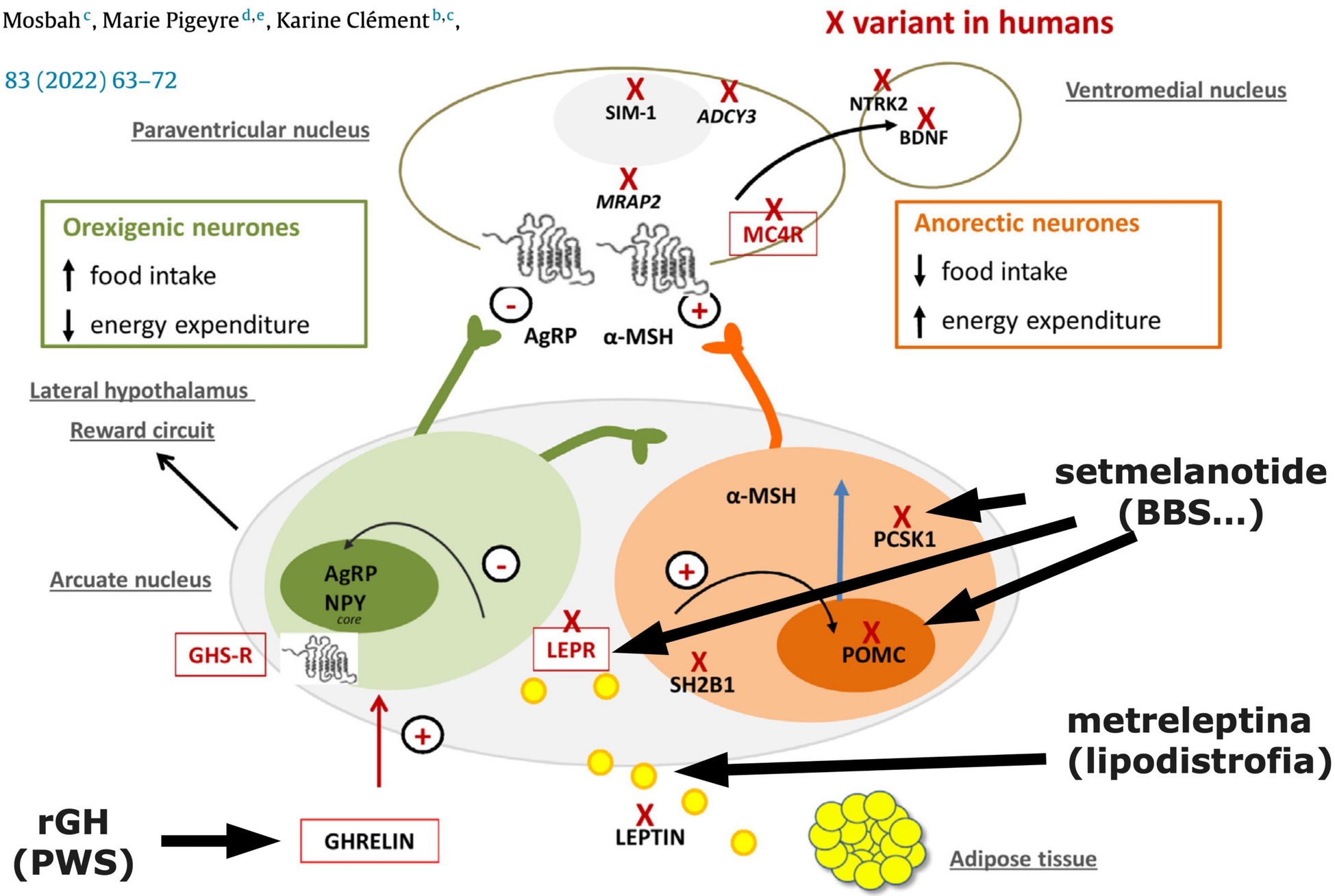

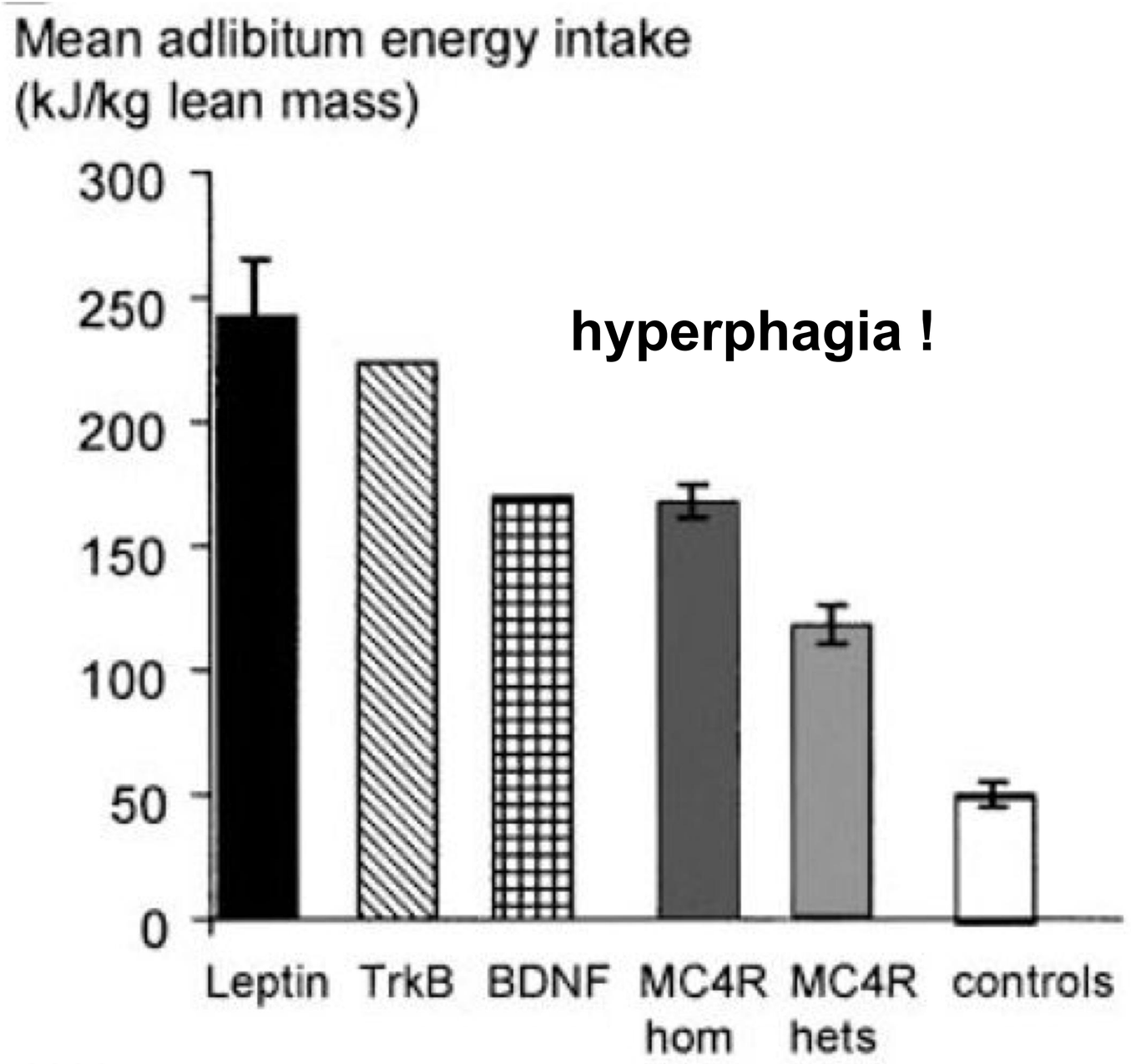

hyperphagia !

Gray et al, Diabetes 2006

Early childhood height, weight, and BMI development in children with monogenic obesity: a European multicentre, retrospective, observational study

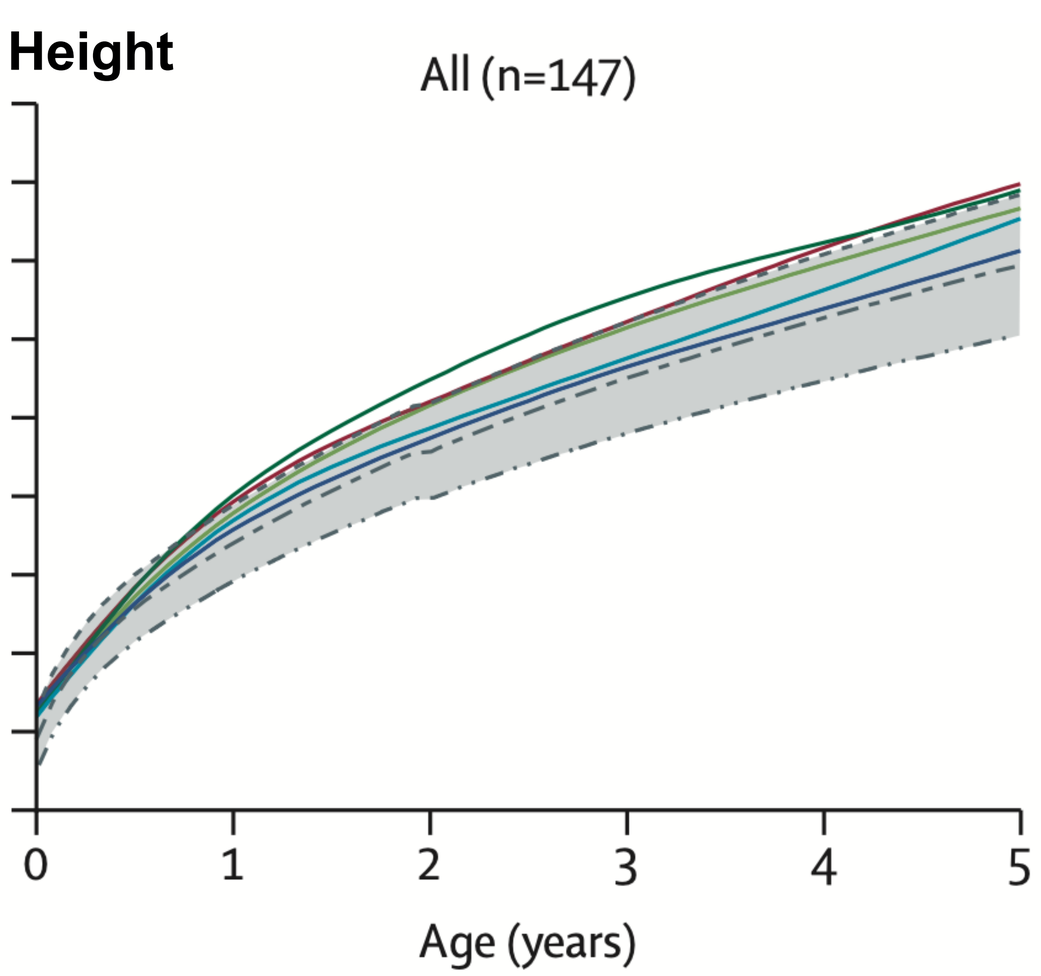

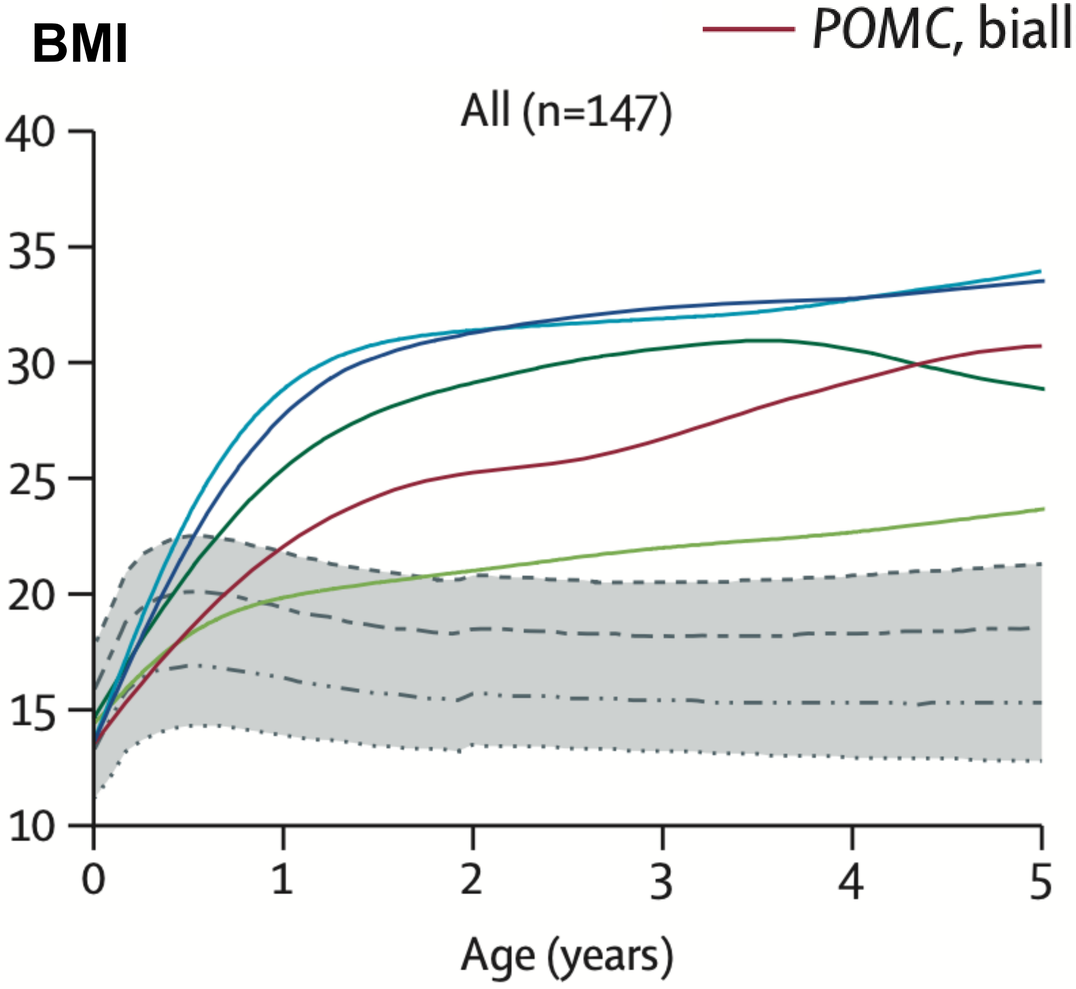



S. Zorn et al, Lancet Child Adolesc Health 2025

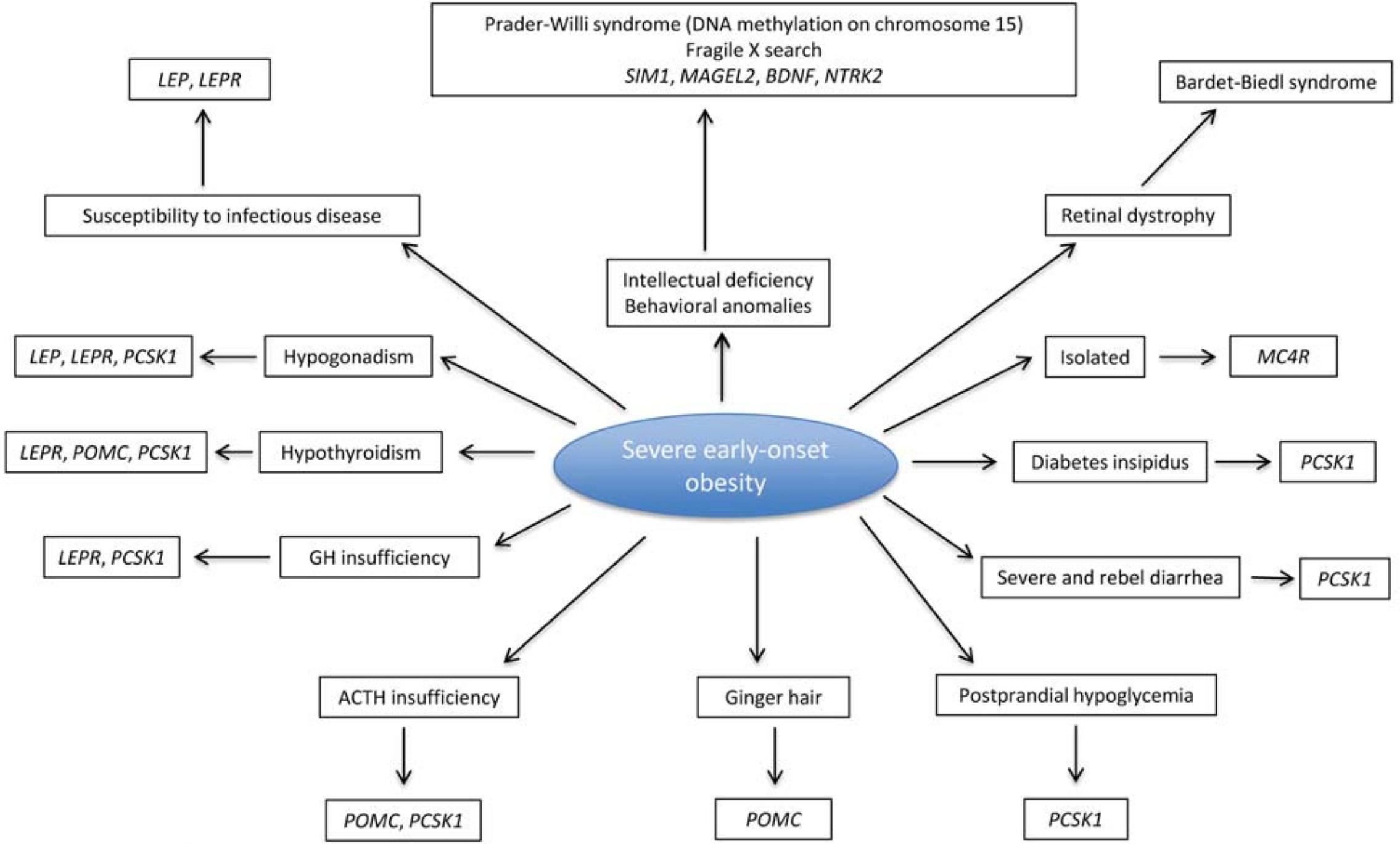

Huvenne et al, Obesity Facts 2016

POMC deficiency syndrome

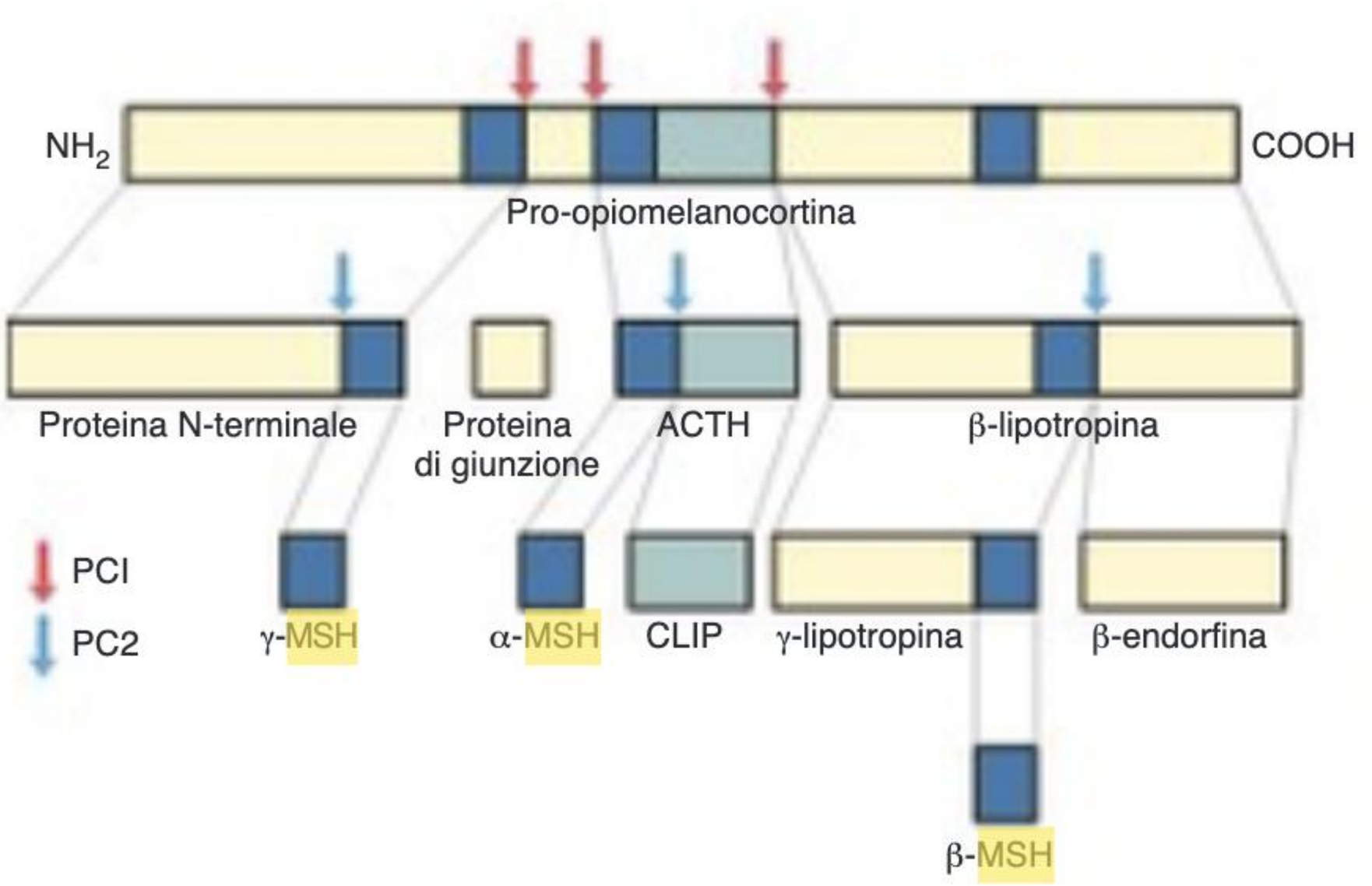

Guyton & Hall, Fisiologia Medica XIV edizione 2021

POMC deficiency syndrome



Krude & Gruters, TEM 2000



Gregoris et al,
Frontiers in Endocrinology 2021



Mark et al,
J Ped Endocrinol Metab 2018

Biallelic pathogenic variants in *POMC* can cause combined pituitary hormonal deficiency associated with severe obesity

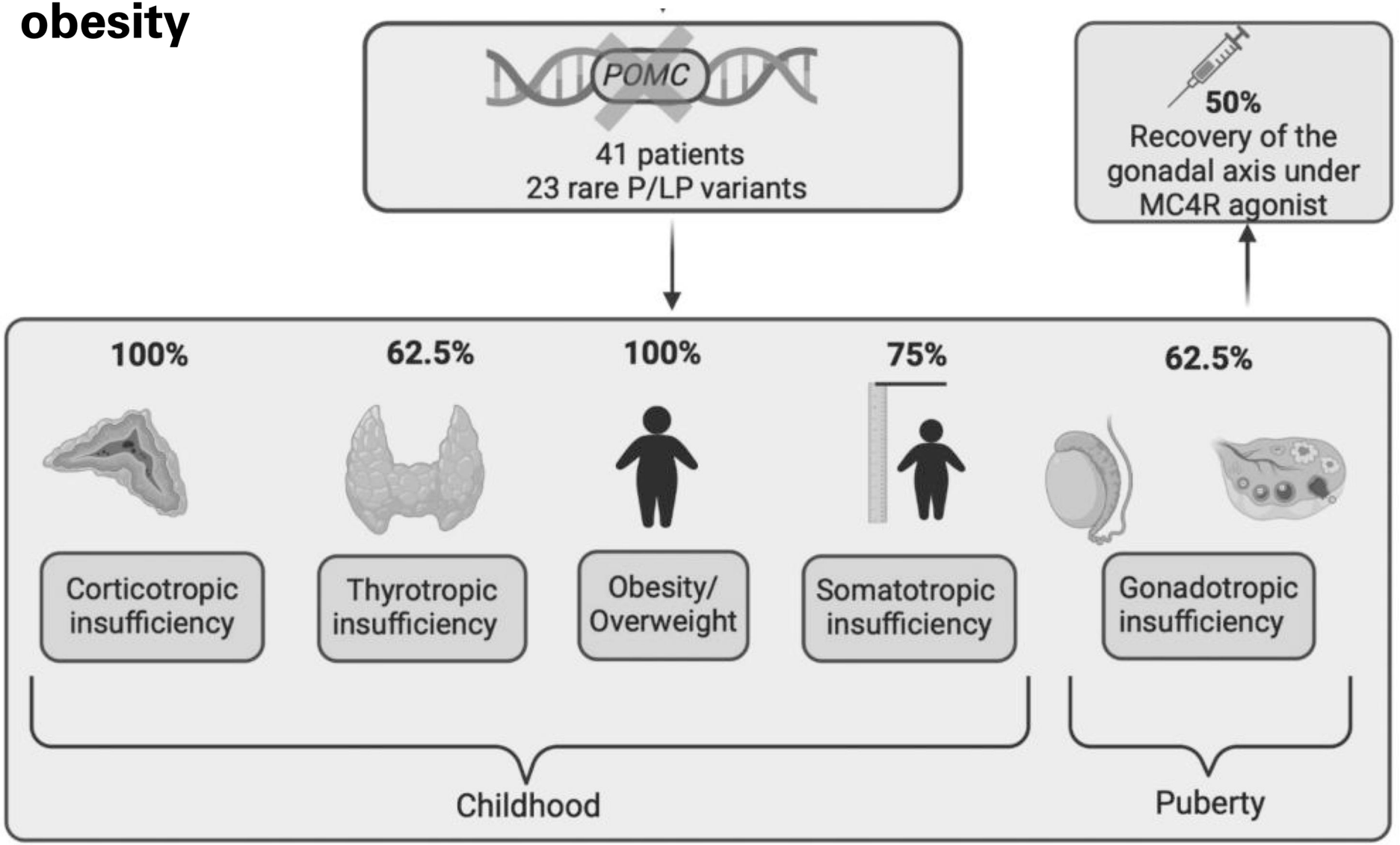

Vitellius et al, EJE 2025

Deficit di Leptina

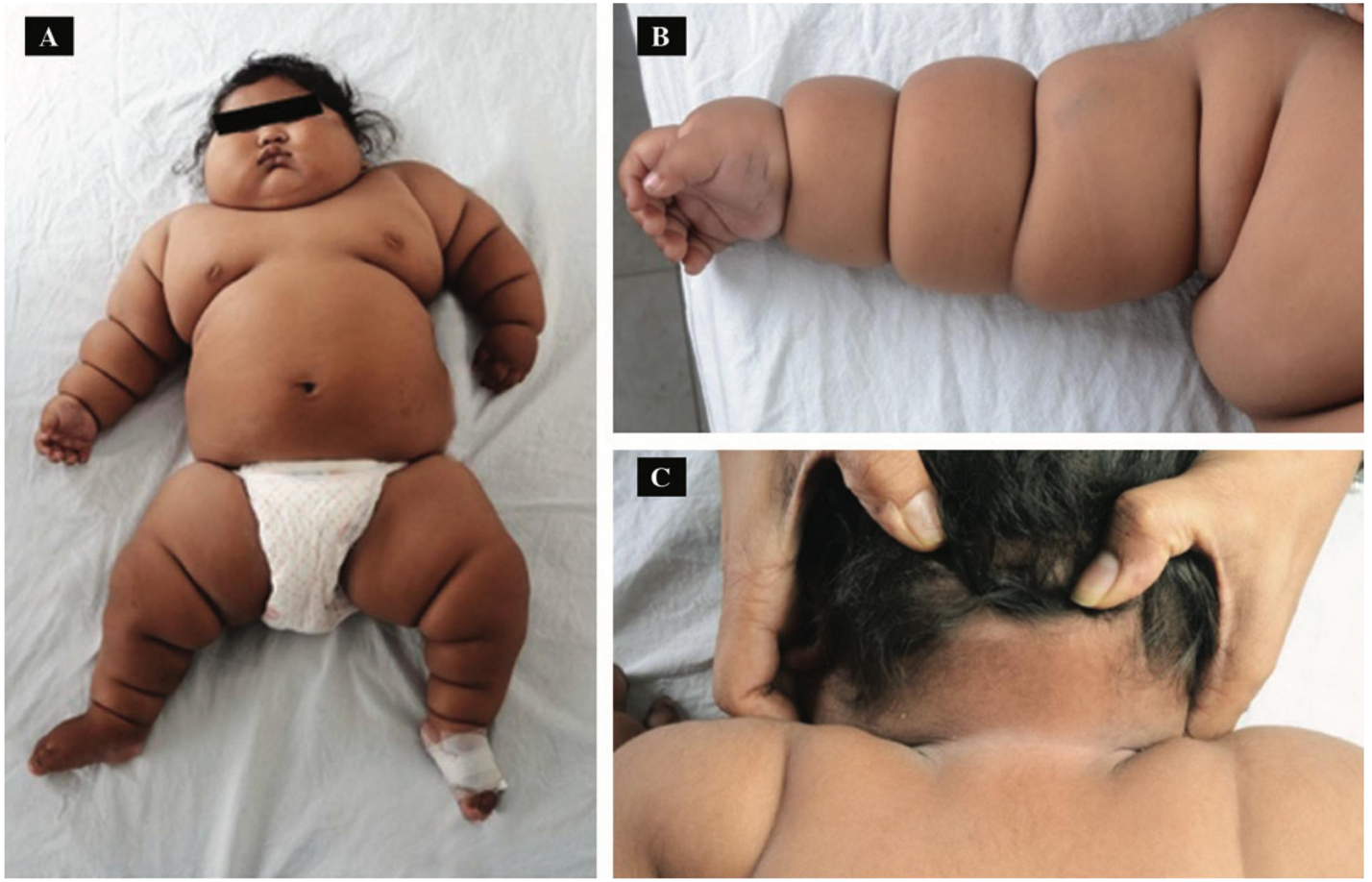

Figure 1. Clinical photographs of the patient showing A) generalized body fat distribution, B) deep skin folds and C) acanthosis nigricans

Dayal et al, J Clin Res Pediat Endocrinol 2018

Leptina biologicamente non attiva

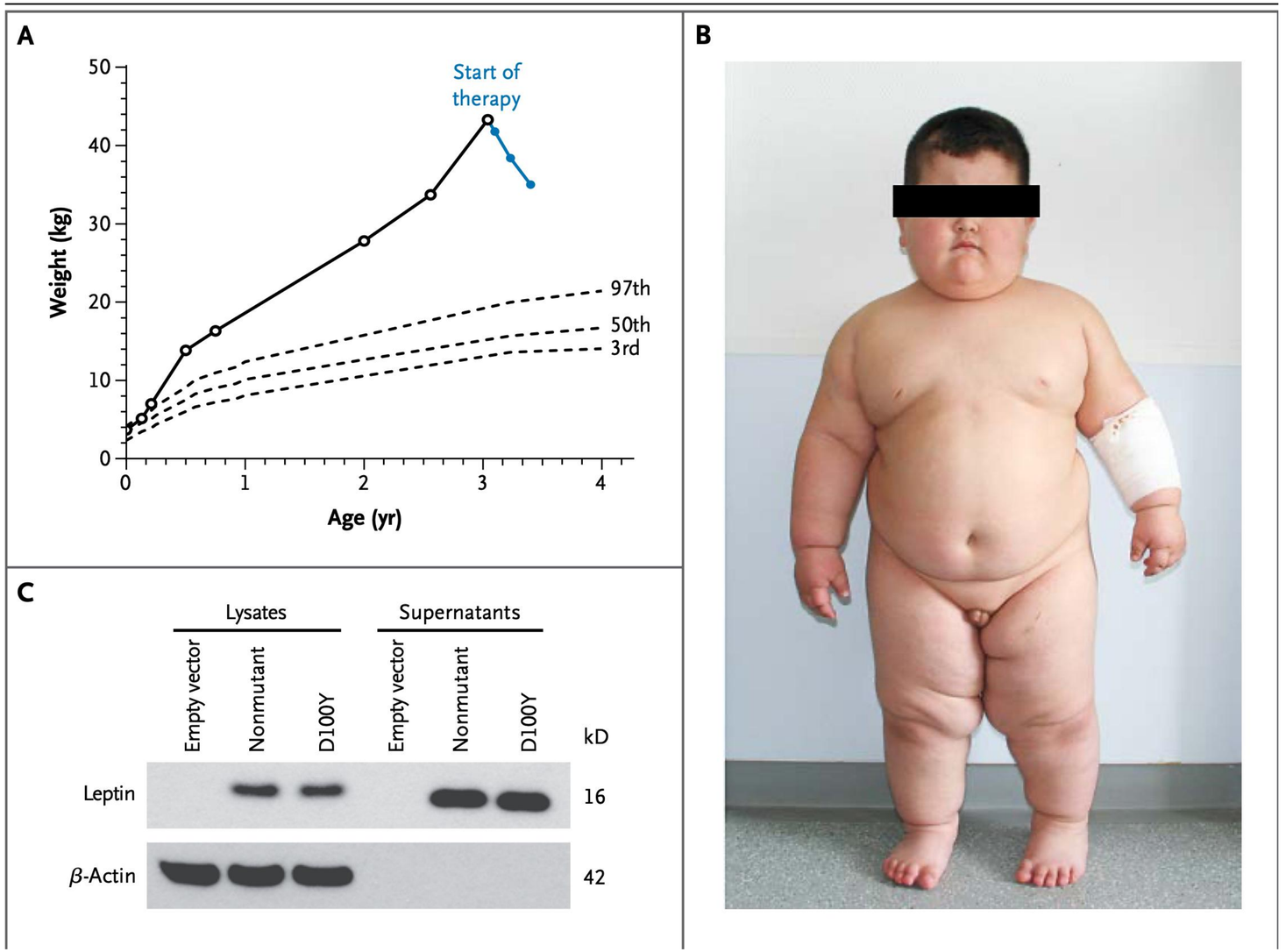

Wabitsch et al, NEJM 2015

Mutazione del recettore della Leptina





Boro et al, Pediatr Endocrinol Diabetes Metab 2023

Effects of leptin deficiency on human body.

Created with Biorender.com.

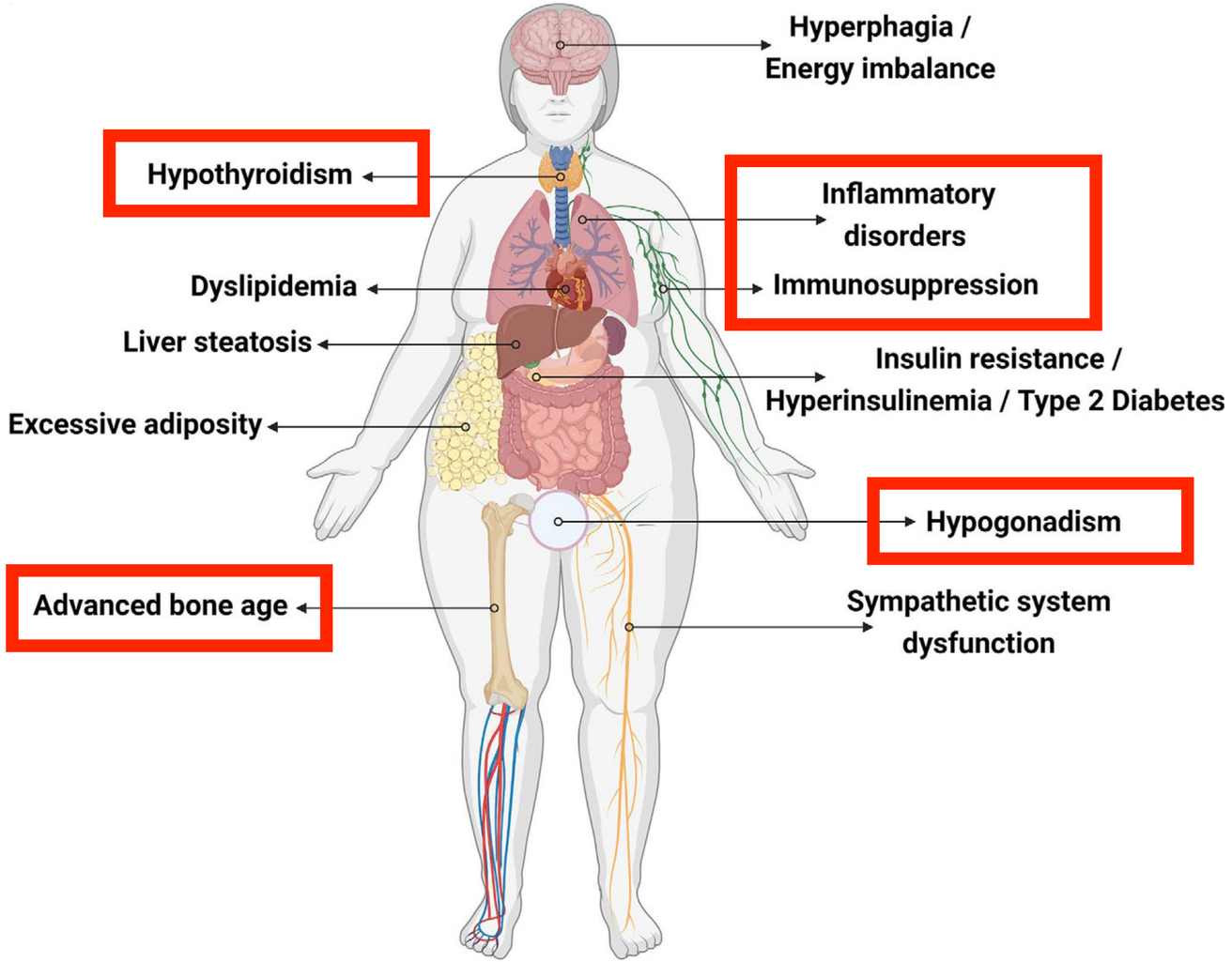

Distribution of types of mutations and gender among cases.

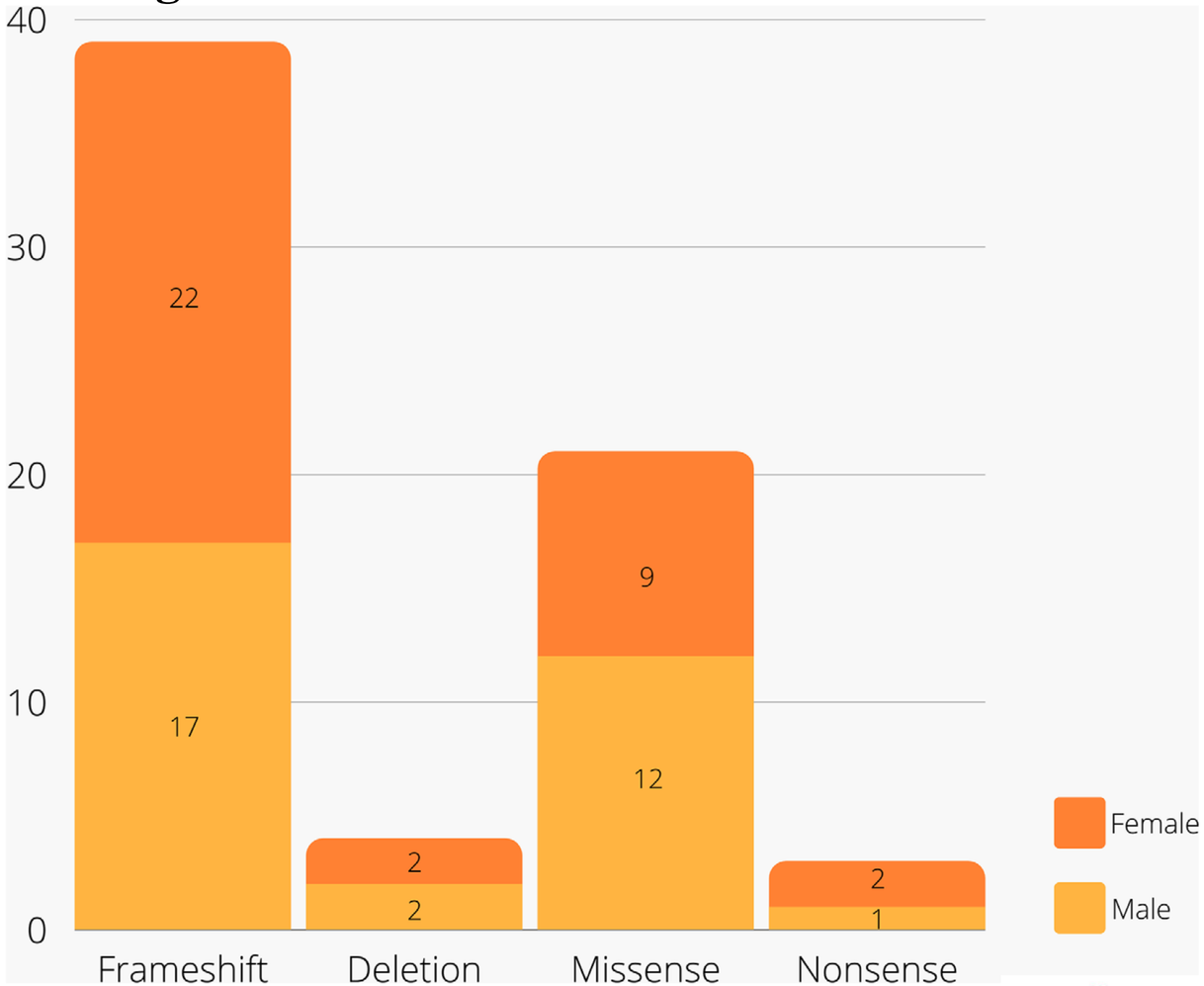

Salum et al, Frontiers in Endocrinology 2021

Mutazione del recettore 4 della melanocortina

Trasmissione autonomia dominante
6% dei pazienti con obesità infantile
1-2.5% dei pazienti con BMI > 30 Kg/m2 eterozigoti per MC4R

Omozigosi:
- obesità
- Iperfagia lieve
- Aumento massa magra
- Aumento densità mineralizzazione ossea
- Aumento crescita lineare nella prima infanzia
- Iperinsulinemia grave
- Funzione riproduttiva conservata
- Lieve ipotiroidismo centrale



Diverse Obesity Trajectories in a Family Including Identical Twins with a Pathogenic *MC4R* Variant



Lim et al, Obesity Facts 2025





FIGURE 1: Right hand - polysyndactyly; left hand - polydactyly



FIGURE 2: Polydactyly of the left foot

Kumar et al, Cureus 2020



FIGURE 1: The obese boy shows a round face, double chin, gynecomastia, and pendulous abdomen



FIGURE 2: Polydactyly in the foot of the boy



FIGURE 3: Polydactataly in the hand of the boy



Thadchanamoorthy et al, Cureus 2021

The Disease Profile & The Ciliopathy Web

Core Pathology

Bardet-Biedl Syndrome (BBS) is a fully penetrant, highly disabling autosomal recessive ciliopathy. Pathogenesis is rooted in primary cilia dysfunction. One cellular defect cascades into multi-organ failure.

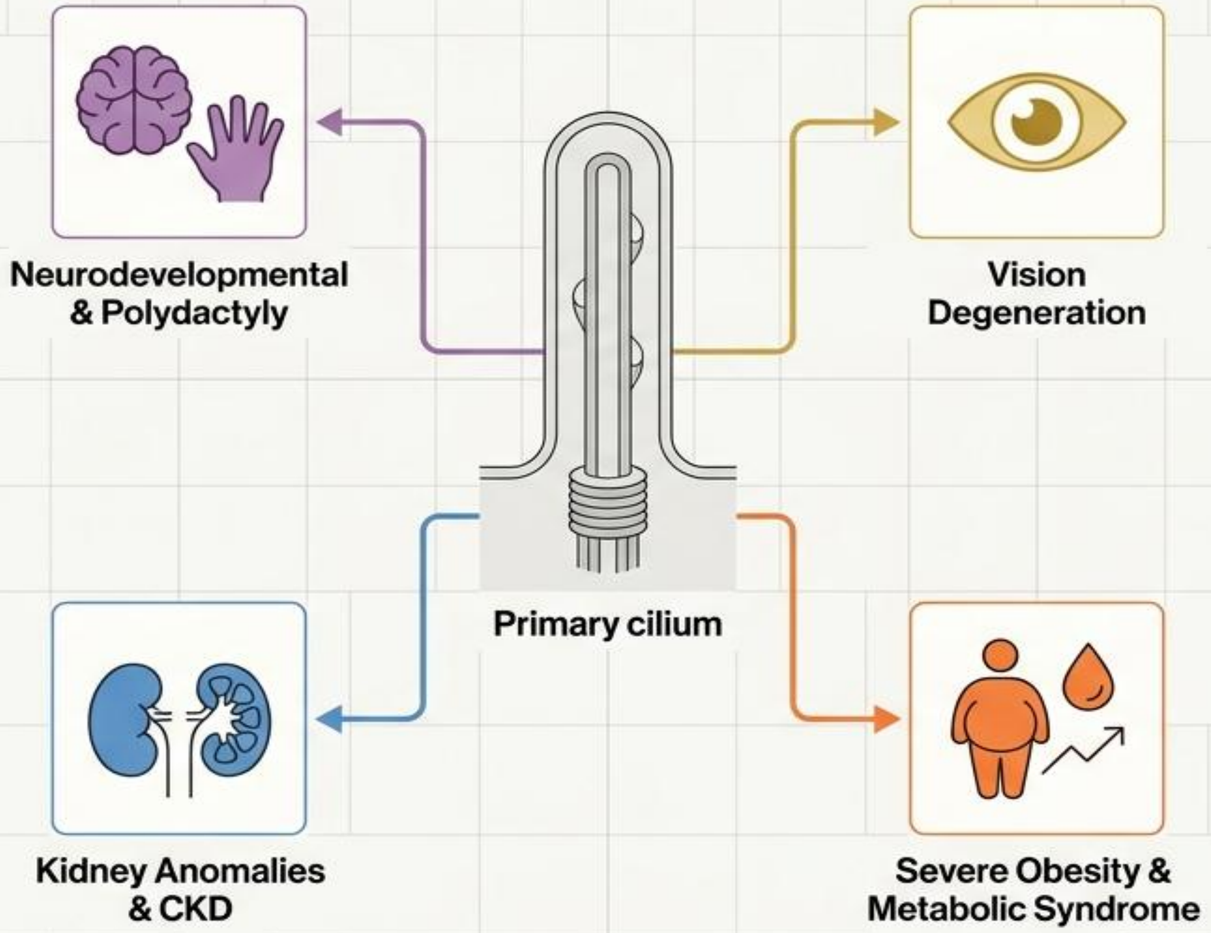

Global Prevalence

~1:160,000

Isolated Communities

Up to ~1:15,000

Onset & Progression

Asynchronous. Detectable in utero; progresses continuously throughout lifespan.

H. Dollfus et al, European Journal of Human Genetics 2024

Clinical Hallmarks: Defining the Criteria

Separating primary pathological drivers from secondary manifestations

Primary Clinical Criteria

- Polydactyly
- Early Obesity
- Early-Onset Retinal Dystrophy
- Kidney Anomalies / Dysfunction
- In Utero Exception: Hyperechogenic kidneys (replaces dystrophy/obesity)

Secondary Clinical Criteria

- Hydrometrocolpos (Female)
- Micropenis / Hypogonadism (Male)
- Neurodevelopmental Disability (NDD)
- Anosmia / Hyposmia
- In Utero Exception: Situs inversus

H. Dollfus et al, European Journal of Human Genetics 2024

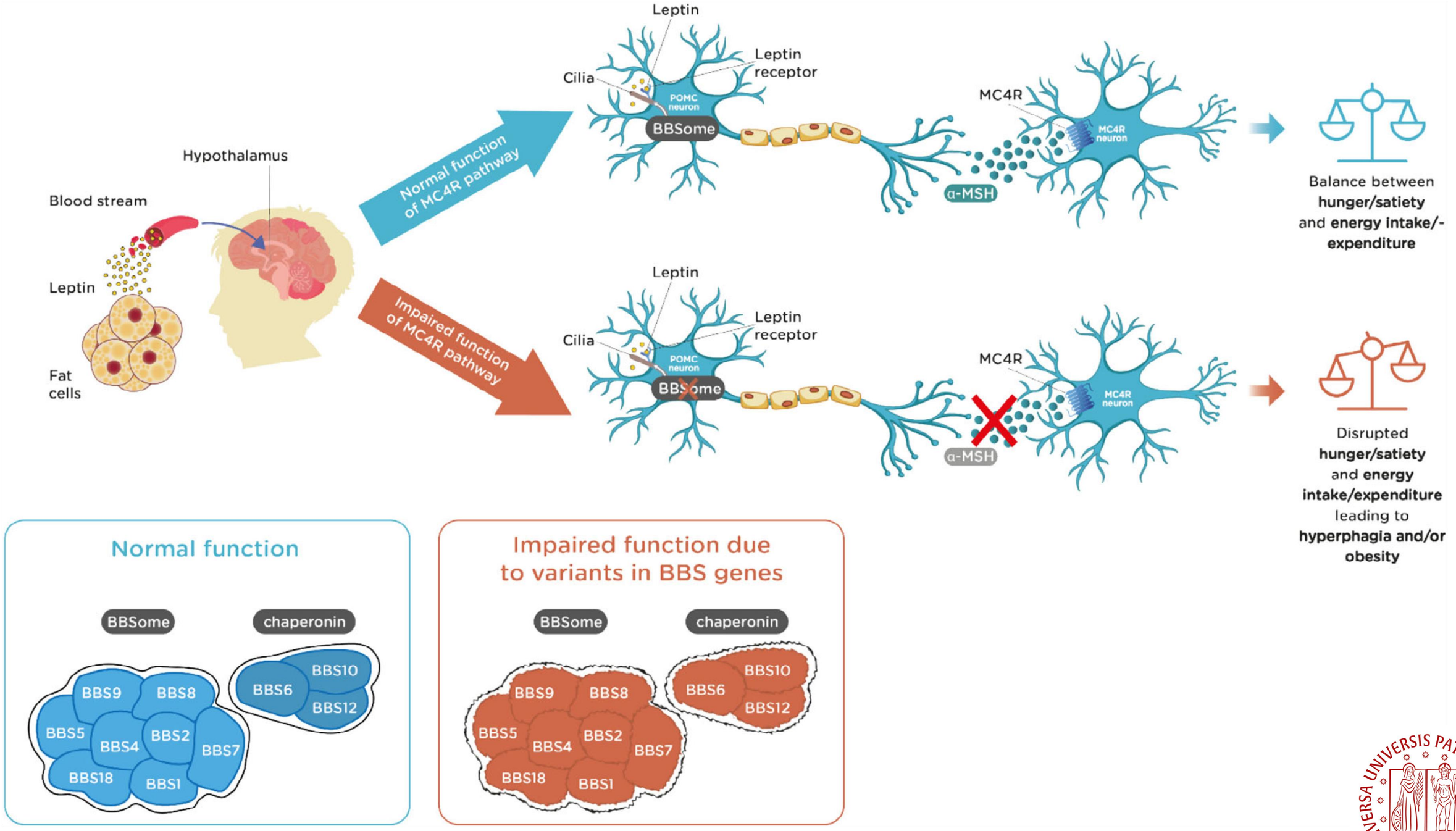

P Beales et al, Obesity Reviews 2025

The Differential Diagnosis: Navigating Allelic Overlap

Core Concept: Some BBS-associated genes also cause distinctly different syndromic ciliopathies. Do not rely on genetics alone without a thorough clinical match.

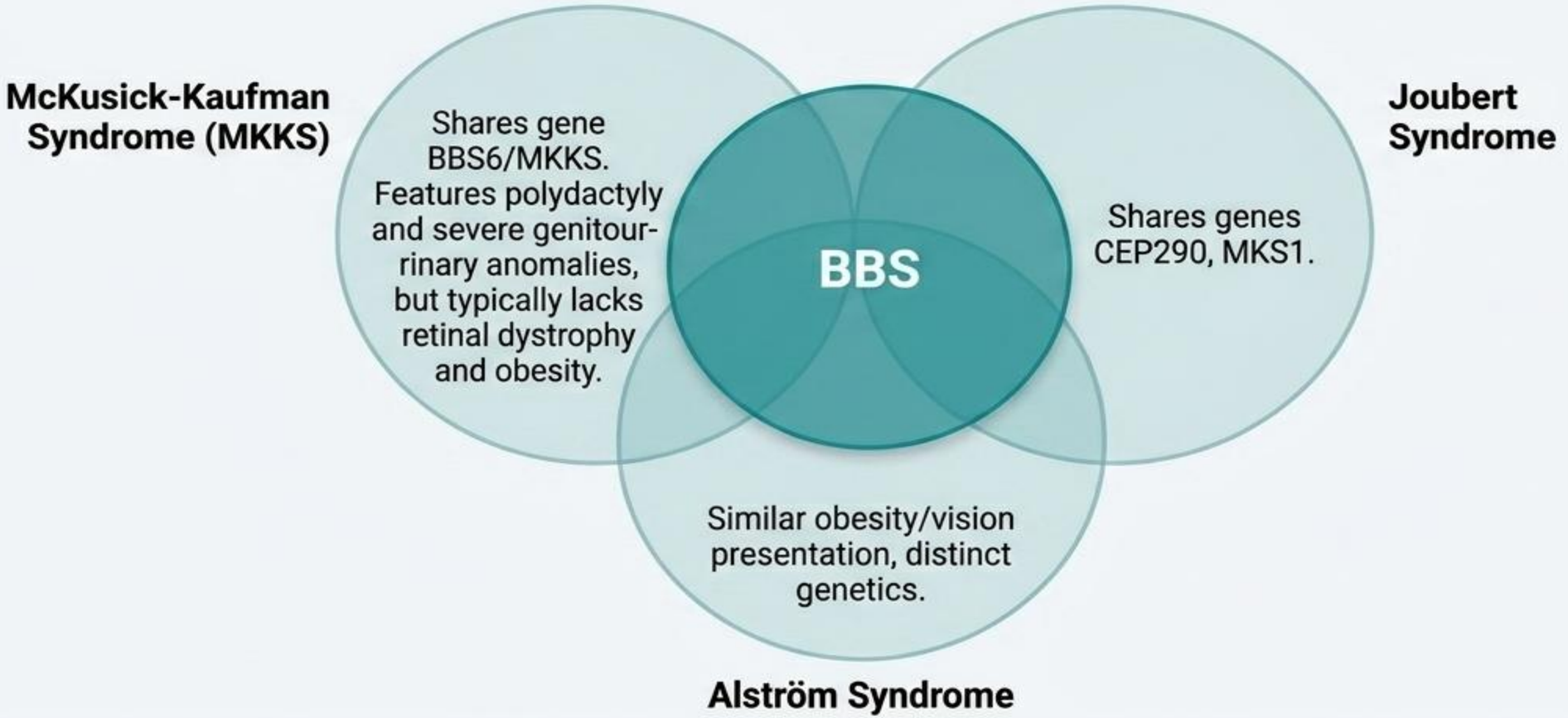

Takeaway: Genetic findings must always be interpreted strictly within the context of the patient's specific clinical phenotype.

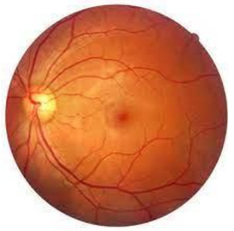

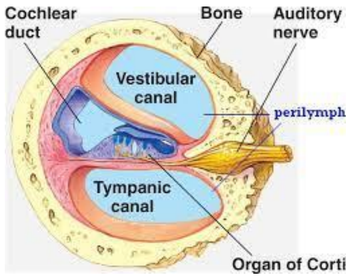

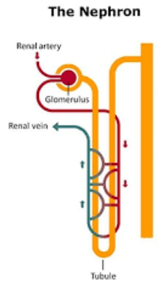

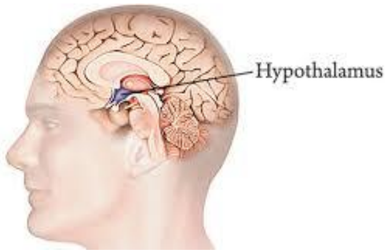

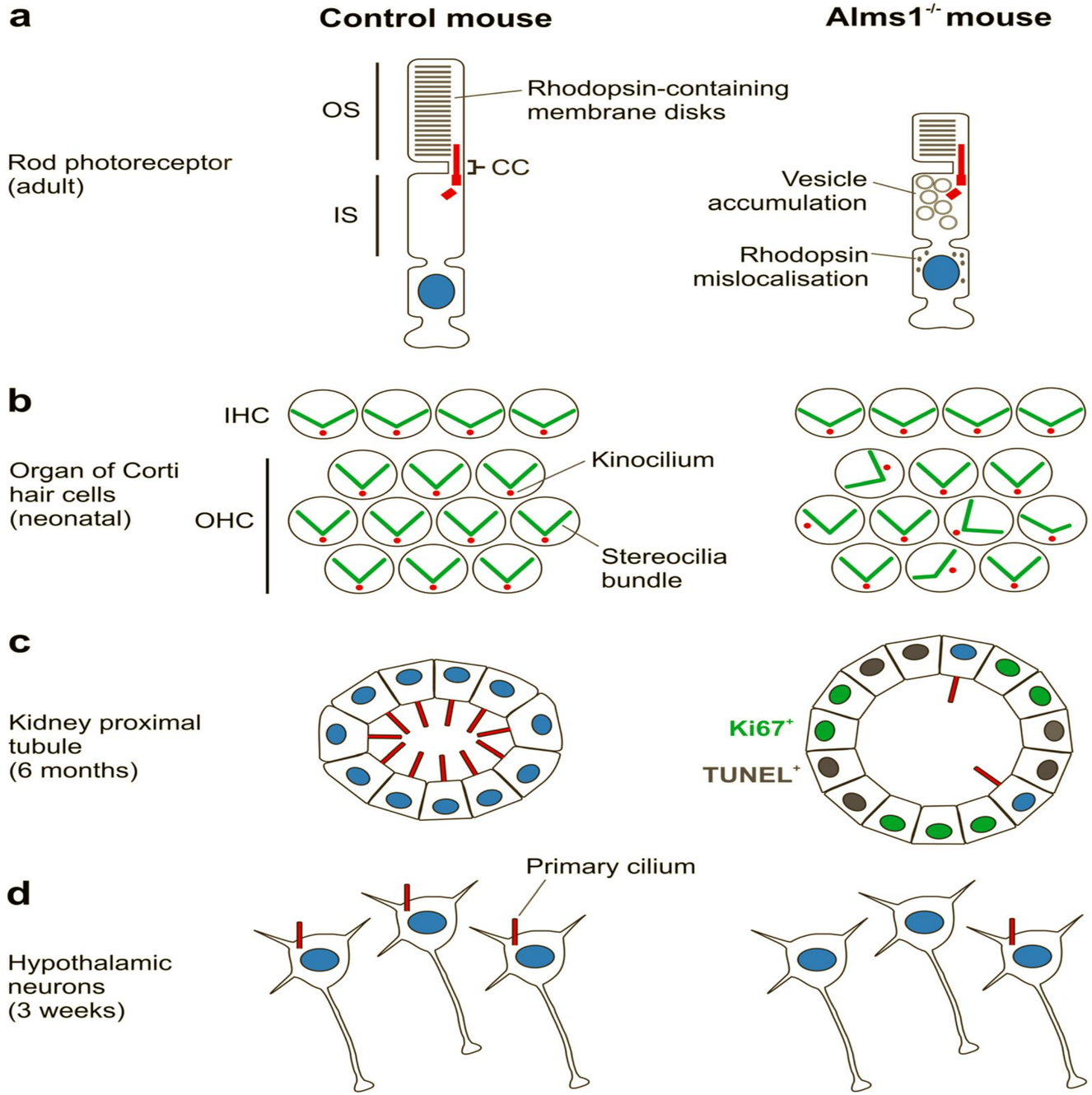

T Hearn, Journal of Molecular Medicine 2019

Alström Syndrome Phenotype



- Autosomal recessive
- Prevalence < 1:1.000.000
- Cone-rod dystrophy
- Hearing loss
- Obesity
- Hyperinsulinemia, T2DM
- Hypertriglyceridemia
- DCM, Liver, kidney failure
- Systemic fibrosis

Subcutaneous Fat Accumulation

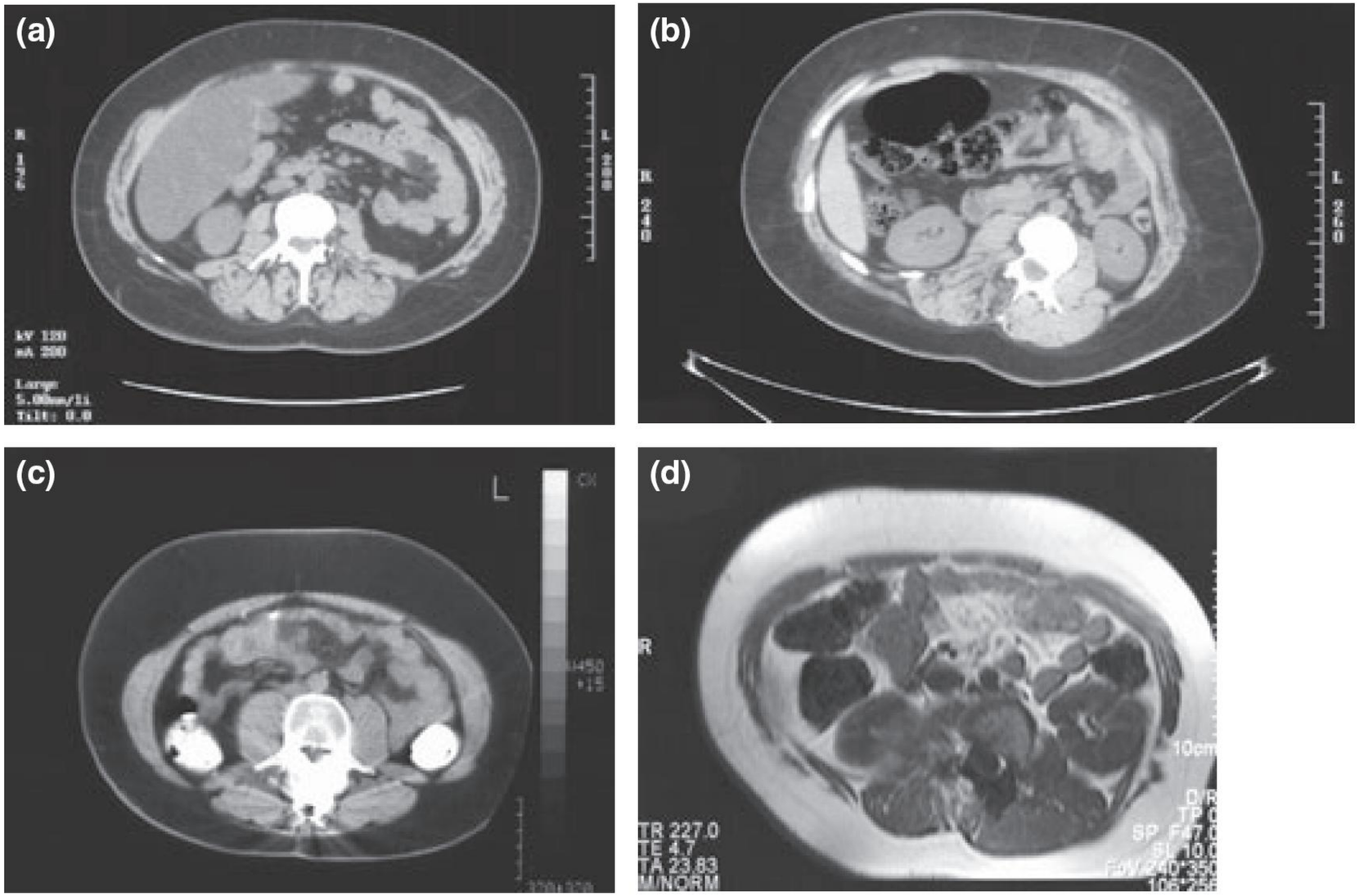

R Paisey et al, J Hum Nutr Diet, 2008


OKTOBARFEST
NOTSOBERFEST





Obesity, Severe Insulin Resistance with Acanthosis Nigricans, Diabetes





Take Home Message

- Think beyond common diseases - hypothalamic obesity exist!
- Collect detailed family history
- Recognize red flags - atypical features should prompt investigation
- Consider genetic testing when criteria met
- Don't focus on single function, organ or systems: consider the whole clinical picture !
- Refer to specialists when uncertain
- Correct diagnosis changes management - not just academic exercise

Grazie !

